

Grant Agreement Number ECP-2006-EDU-410030

eViP

**Inventory of existing VP cases complete with any
IPR issues and report on which VP cases that will be
repurposed, medical/healthcare speciality targeted
and responsible partner**

Deliverable number *D3.1*

Dissemination level *Restricted*

Delivery date *29th February 2008*

Status *Final*

Author(s) *The eViP Project Team:*

St George's, University of London (SGUL)

Karolinska Institutet (KI)

Ludwig-Maximilians-Universitaet Muenchen (LMU)

The University of Warwick (WAR)

Universiteit Maastricht (UM)

The Faculty of Medicine at Heidelberg University (HD)

*University of Medicine and Pharmacy "Iuliu Hatieganu" Cluj-Napoca
(CLUJ)*

Uniwersytet Jagiellonski (UJ)



eContentplus

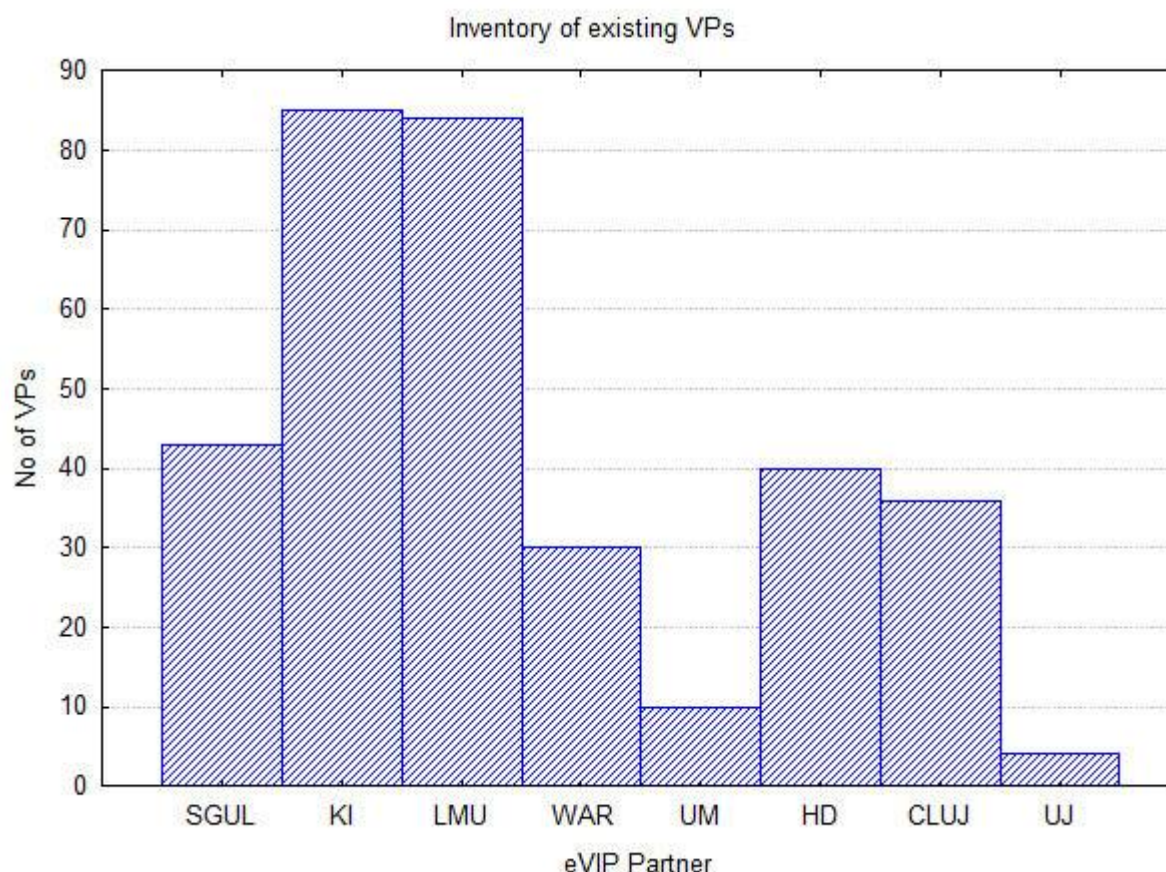
This project is funded under the eContentplus programme¹, a multiannual Community programme to make digital content in Europe more accessible, usable and exploitable.

¹ OJ L 79, 24.3.2005, p. 1.

Background

This report summarises the key findings from a detailed inventory undertaken by the eViP team. The complete inventory can be found in Annex A and the statistical analysis used to summarise the findings below can be found in Annex B. Both annexes are available at the end of this report.

Number of Virtual Patients:



Partner	Number of VPs	Currently stored in
St Georges	43	OpenLabyrinth
Karolinska Institutet	85	Web-SP
Munich	84	Casus
Warwick	30	Ivimeids
Maastricht	10	Campus
Heidelberg	40	Campus
Cluj	36	Web-SP
Jagiellonian University	4	Casus

Inventory of existing VP cases complete with any IPR issues and report on which VP cases that will be repurposed, medical/healthcare speciality targeted and responsible partner

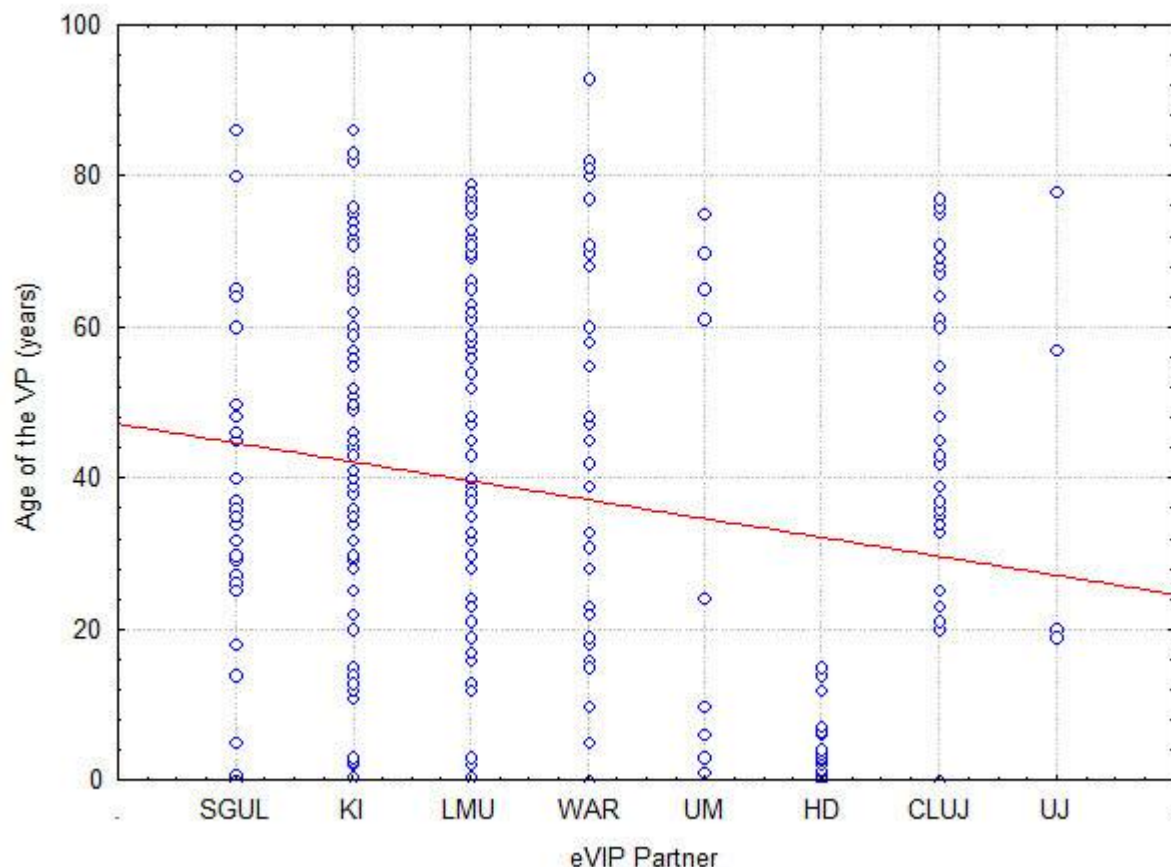
eViP – Electronic Virtual Patient
www.virtualpatients.eu

All	332	
-----	-----	--

Age of the Virtual Patients

The mean age of the VPs contributed by the eVIP partners is 38,5 years with a large spread in age (SD: 24,8).

The youngest VP is a newborn and the oldest is 93 years old.



Gender of the Virtual Patients

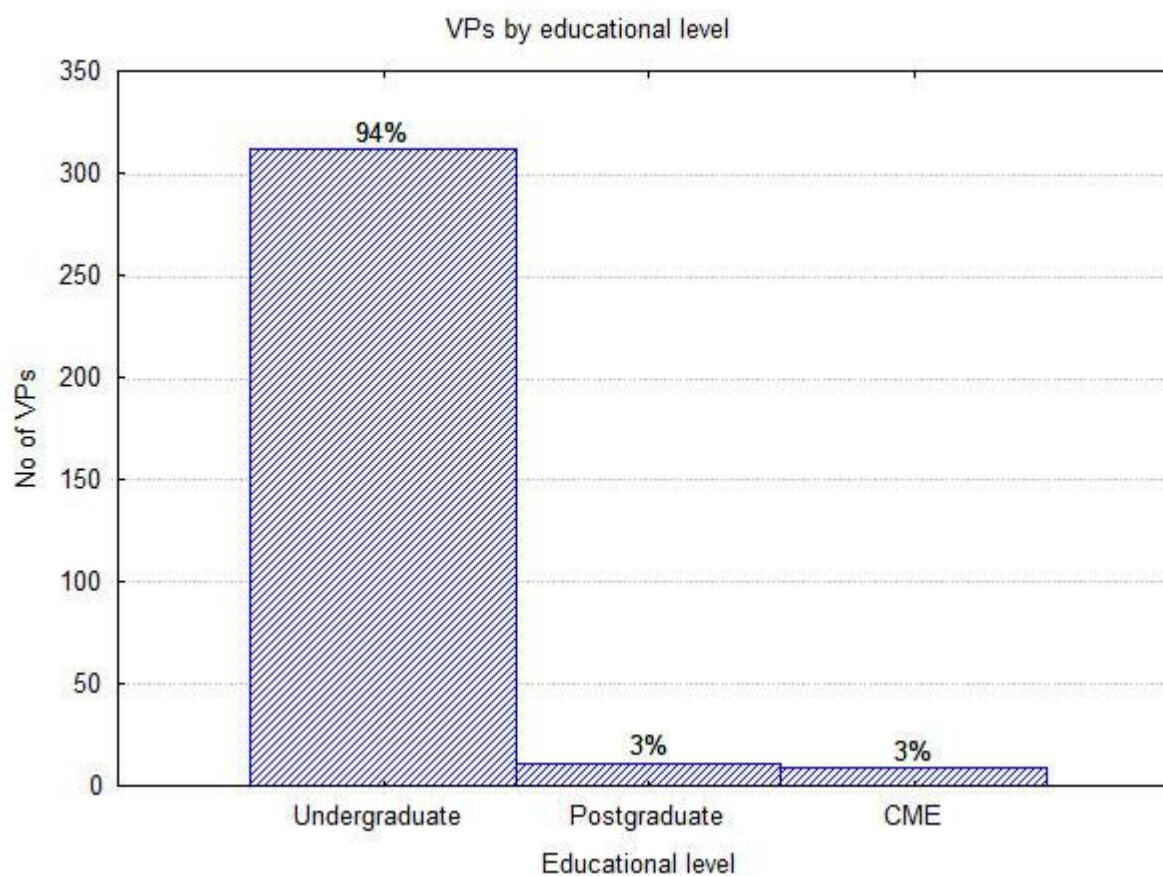
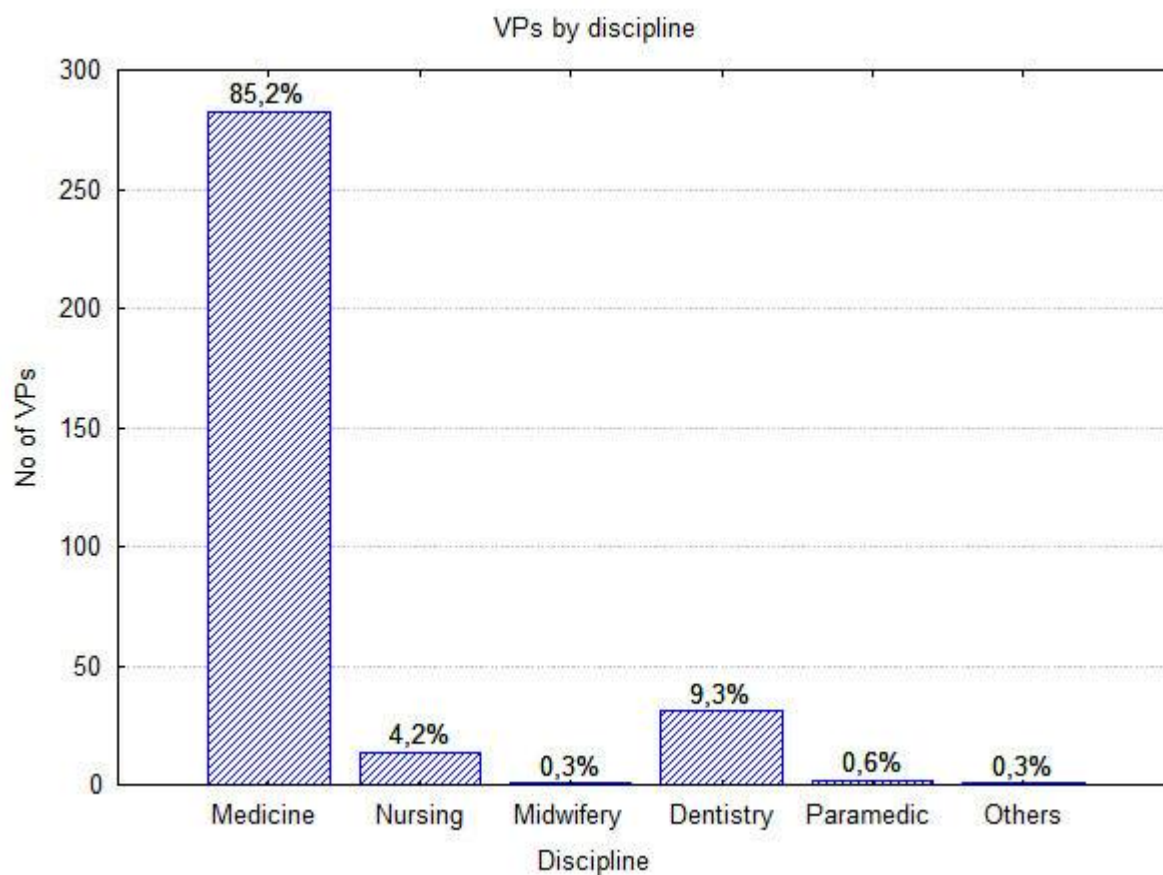
The inventory contains an almost equal proportion of female (51%) and male (49%) VPs.

Discipline and Educational level

Most of the VPs in the inventory are for Medicine (85%) and primarily aiming at the undergraduate level (94%).

Other disciplines and educational levels are present but represented in a much lesser extent. The majority of the submitted VPs (88%) have already been used by students.

Inventory of existing VP cases complete with any IPR issues and report on which VP cases that will be repurposed, medical/healthcare speciality targeted and responsible partner

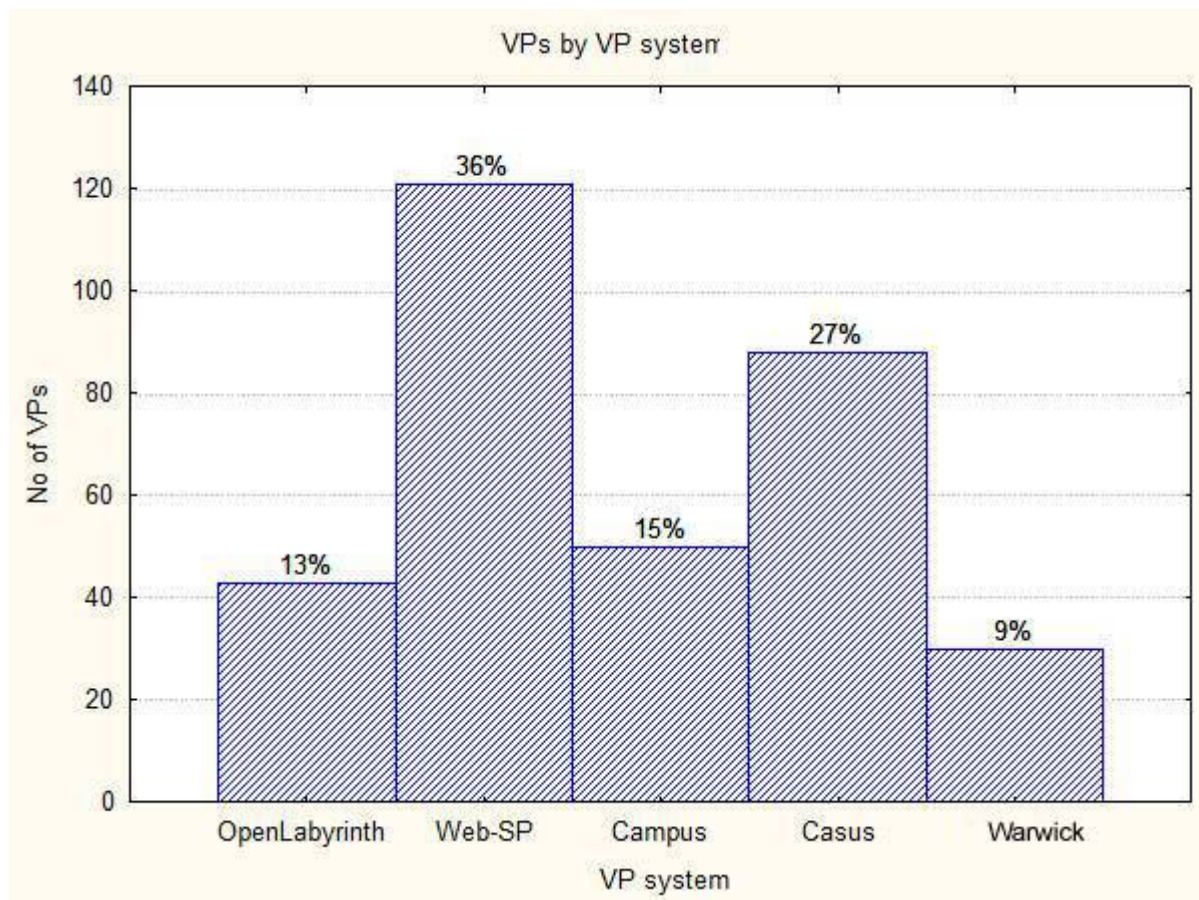


Inventory of existing VP cases complete with any IPR issues and report on which VP cases that will be repurposed, medical/healthcare speciality targeted and responsible partner

eViP – Electronic Virtual Patient
www.virtualpatients.eu

Current location

All the VPs are currently stored in the following VP systems with restricted access.

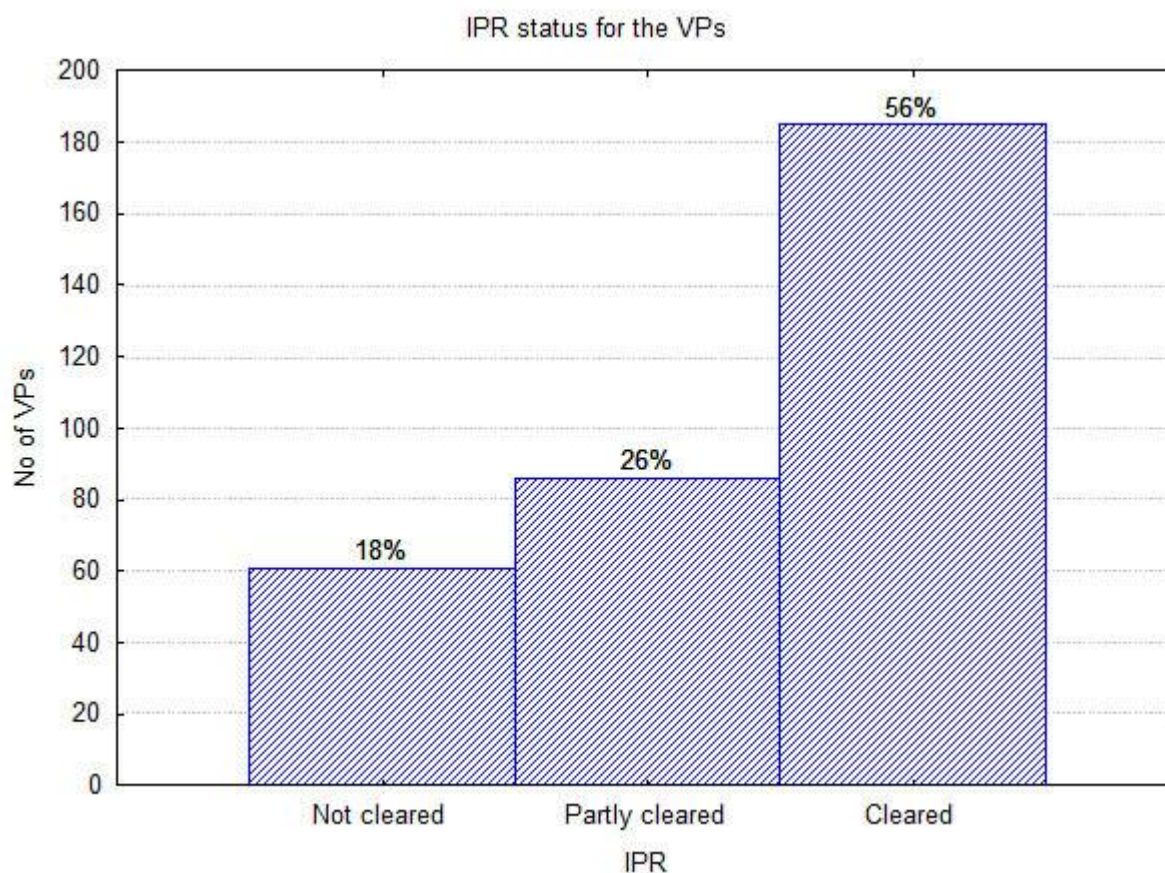


IPR

Half of the VPs (56%) have a cleared IPR status for sharing. The process is still ongoing for the remaining VPs.

Inventory of existing VP cases complete with any IPR issues and report on which VP cases that will be repurposed, medical/healthcare speciality targeted and responsible partner

eViP – Electronic Virtual Patient
www.virtualpatients.eu

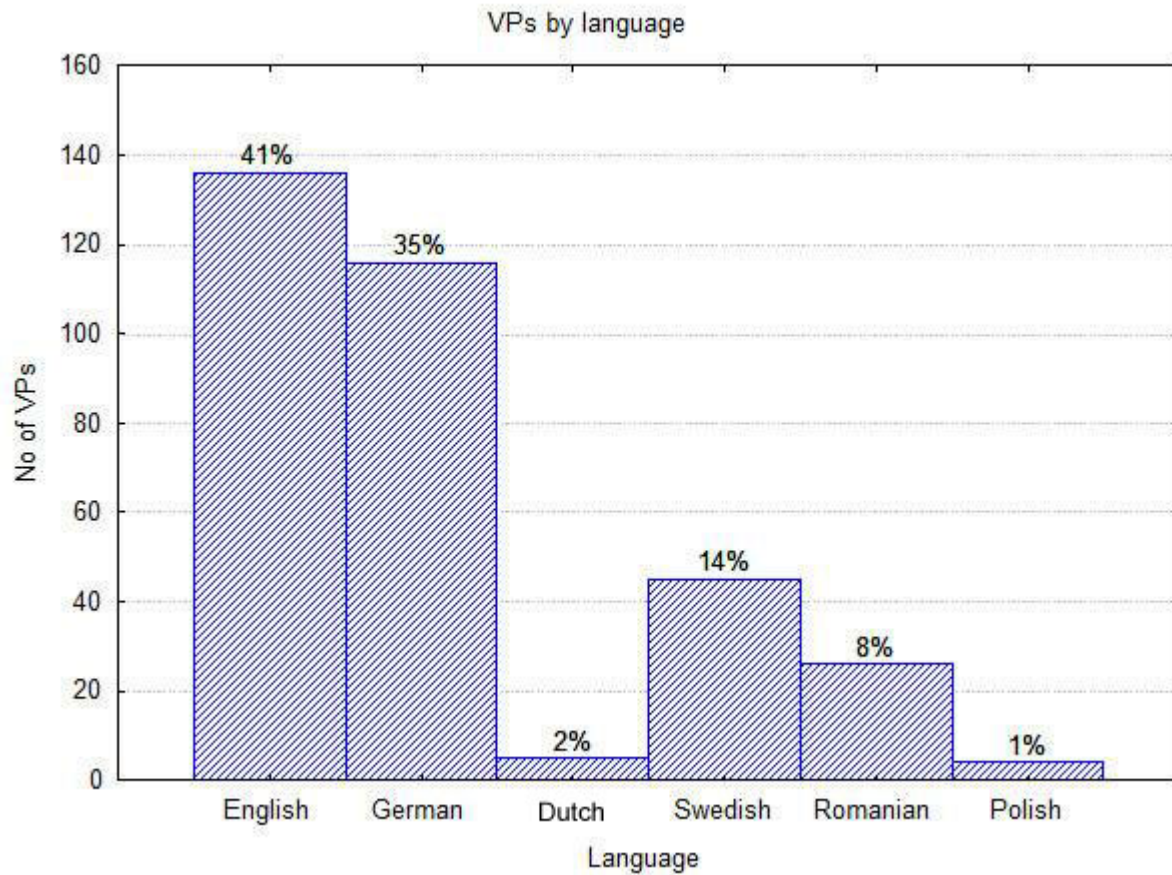


Multilingual inventory

The inventory is truly multilingual with six languages represented with English (41%) and

Inventory of existing VP cases complete with any IPR issues and report on which VP cases that will be repurposed, medical/healthcare speciality targeted and responsible partner

German (35%) as the two most spoken languages. This is to be expected as two partners are from the UK (SGUL and WAR) and two partners are from Germany (LMU and HD).



Annexes:

Annex A – Complete inventory

Annex B – Statistical findings (raw data)

Annex C – Project plan for deliverable 3.1

Inventory of existing VP cases complete with any IPR issues and report on which VP cases that will be repurposed, medical/healthcare speciality targeted and responsible partner

eViP – Electronic Virtual Patient
www.virtualpatients.eu

Annex A – Complete inventory

Ref ID	Institution	VP Title	VP Age	VP Sex	Discipline e.g medicine, nursing	Clinical topics	Brief description	Educational level	URL if available	VP system	IPR (Cleared/Partly cleared/Not cleared)	Language	Access rights	Has been used by students?	Contact name	Contact email
SGULeVI P001	SGUL	Henry Rodin	40	M	Medicine	lobar pneumonia	collapse during a remote hiking trip, and subsequent management	pre-clinical undergraduate	Available on request	Labyrinth	cleared	English	restricted access	yes	T Poulton	tpoulton@squ.ac.uk
SGULeVI P002	SGUL	Pat Hurst	65	F	Medicine	multiple myeloma	Back pain, bone, lytic lesions	pre-clinical undergraduate	Available on request	Labyrinth	cleared	English	restricted access	yes	T Poulton	tpoulton@squ.ac.uk
SGULeVI P003	SGUL	Michael Burton	14	M	Medicine	Acute Lymphoid leukemia	Haematological malignancy, principles of management, psychosocial issues raised by potentially fatal illness of a family member	clinical undergraduate	Available on request	Labyrinth	cleared	English	restricted access	yes	T Poulton	tpoulton@squ.ac.uk
SGULeVI P004	SGUL	Colin Dale	64	M	Medicine	Colonic carcinoma	presentation of gastro-intestinal bleeding, surgical removal of tumour	clinical undergraduate	Available on request	Labyrinth	partly cleared	English	restricted access	yes	T Poulton	tpoulton@squ.ac.uk
SGULeVI P005	SGUL	Toni Hutchins on:	26	F	Medicine	Food allergy	Presentation and management of anaphylactic response to peanuts	clinical undergraduate	Available on request	Labyrinth	partly cleared	English	restricted access	yes	T Poulton	tpoulton@squ.ac.uk
SGULeVI P006	SGUL	Dave Hutchins on	27	M	Medicine	Food poisoning	Campylobacter, presentation, management and public health issues	clinical undergraduate	Available on request	Labyrinth	partly cleared	English	restricted access	yes	T Poulton	tpoulton@squ.ac.uk
SGULeVI P007	SGUL	Joseph Ansah	34	M	Medicine	Malaria	Treatment and diagnosis, alternative therapy, treating asylum seekers	clinical undergraduate	Available on request	Labyrinth	partly cleared	English	restricted access	yes	A Somasundaram	asomasun@squ.ac.uk
SGULeVI P008	SGUL	Mercy Juma	26	F	Medicine	HIV	Refugee with HIV, Malaria, Opportunistic Infections,	clinical undergraduate	Available on request	Labyrinth	partly cleared	English	restricted access	yes	A Somasundaram	asomasun@squ.ac.uk
SGULeVI P009	SGUL	John Payne	60	M	Medicine	Tuberculosis	2 linked cases covering two generations of tuberculosis illustrating changes in management.	clinical undergraduate	Available on request	Labyrinth	partly cleared	English	restricted access	yes	T Poulton	tpoulton@squ.ac.uk
SGULeVI P010	SGUL	Edward Payne	29	M	Medicine	Tuberculosis	3 generations of tuberculosis illustrating changes in management	clinical undergraduate	Available on request	Labyrinth	partly cleared	English	restricted access	yes	T Poulton	tpoulton@squ.ac.uk
SGULeVI P011	SGUL	Chris James	18	M	Medicine, nursing, physicians' assistants	Diabetic keto-acidosis	initial assessment and management	clinical undergraduate	Available on request	Labyrinth	partly cleared	English	restricted access	yes	T Poulton	tpoulton@squ.ac.uk
SGULeVI P012	SGUL	Mrs Brown	29	F	Midwifery	Wound Infection	Streptococcus group B, wound dressing	clinical undergraduate	Available on request	Labyrinth	partly cleared	English	restricted access	yes	A Atkinson	tpoulton@squ.ac.uk
SGULeVI P013	SGUL	Desmond	50	M	Psychiatry	Psychiatric care	unexplained agitation	clinical undergraduate	Available on request	Labyrinth	partly cleared	English	restricted access	yes	T Poulton	tpoulton@squ.ac.uk
SGULeVI P014	SGUL	Emily Smith	25	F	CPD	Atopic eczema	A patient with atopic eczema presenting in primary care.	clinical undergraduate	Available on request	Labyrinth	partly cleared	English	restricted access	yes	T Poulton	tpoulton@squ.ac.uk
SGULeVI P015	SGUL	George Harrison	46	M	Psychiatry	Mild hyperthyroidism	Stress at work, suicide, SSRIs, use of antidepressants	clinical undergraduate	Available on request	Labyrinth	partly cleared	English	restricted access	yes	T Poulton	tpoulton@squ.ac.uk
SGULeVI P016	SGUL	James	middle-aged	M	Medicine, nursing, physicians' assistants	Chest pain	Palpitation, Thromboprophylaxis,	clinical undergraduate	Available on request	Labyrinth	partly cleared	English	restricted access	yes	T Poulton	tpoulton@squ.ac.uk
SGULeVI P017	SGUL	Malcolm	45	M	Medicine	Acute myocardial infarction	Acute myocardial infarction, treatment	clinical undergraduate	Available on request	Labyrinth	partly cleared	English	restricted access	yes	J Round	j.round@squ.ac.uk
SGULeVI P018	SGUL	Marie hepworth	9 months	F	Medicine	Gastro-enteritis	presentation of diarrhoea and vomiting, treatment for dehydration and shock	clinical undergraduate	Available on request	Labyrinth	partly cleared	English	restricted access	yes	T Poulton	j.round@squ.ac.uk
SGULeVI P019	SGUL	Sarah-Jane	6 months	F	Medicine	Paediatric	Non-accidental injury, coughing, meningitis, encaphilitis, UTI	clinical undergraduate	Available on request	Labyrinth	partly cleared	English	restricted access	yes	T Poulton	j.round@squ.ac.uk

SGULeVI SGUL P020	Shanika	6 months	M	Medicine	Bacterial meningitis	Presentation in A and E of fitting following fever	clinical undergraduate	Available on request	Labyrinth	partly cleared	English	restricted access	yes	T Poulton	j.round@sgul.ac.uk
SGULeVI SGUL P021	Maria H	34	F	Medicine	Acute disc herniation	Acute disc herniation	clinical undergraduate	Available on request	Labyrinth	partly cleared	English	restricted access	yes	T Poulton	tpoulton@sgul.ac.uk
SGULeVI SGUL P022	Samuel R	25	M	Medicine	Ankylosing spondylitis	Ankylosing spondylitis, arthritis, photophobia, mouth ulcers, bamboo spine	clinical undergraduate	Available on request	Labyrinth	partly cleared	English	restricted access	yes	T Poulton	tpoulton@sgul.ac.uk
SGULeVI SGUL P023	Harold H	80	M	Medicine	Prostatic carcinoma	Adenocarcinomas, prostate	clinical undergraduate	Available on request	Labyrinth	partly cleared	English	restricted access	yes	T Poulton	tpoulton@sgul.ac.uk
SGULeVI SGUL P024	Ronnie	7 months	M	Medicine	Endocrine disorder	Endocrine disorder	clinical undergraduate	Available on request	Labyrinth	partly cleared	English	restricted access	yes	T Poulton	j.round@sgul.ac.uk
SGULeVI SGUL P025	Anwar	5	F	Medicine	Pneumonia	Streptococcus pneumoniae, right pleural effusion	clinical undergraduate	Available on request	Labyrinth	partly cleared	English	restricted access	yes	T Poulton	j.round@sgul.ac.uk
SGULeVI SGUL P026	Hannah	5 weeks	F	Medicine	urinary tract infection	E Coli	clinical undergraduate	Available on request	Labyrinth	partly cleared	English	restricted access	yes	T Poulton	j.round@sgul.ac.uk
SGULeVI SGUL P027	Oscar	Term	M	Medicine	resuscitation	infant resuscitation following prolonged labour and caesarian	clinical undergraduate	Available on request	Labyrinth	partly cleared	English	restricted access	yes	T Poulton	j.round@sgul.ac.uk
SGULeVI SGUL P028	Ashad	86	F	Nursing, medicine	Gangreen	Amputation, care plan, inflammation, necrotic toe, infection, pyrexia, phlebitis, pain	clinical undergraduate	NA	Labyrinth	not cleared	English	restricted access	no	T Poulton	tpoulton@sgul.ac.uk
SGULeVI SGUL P029	Berta Apolonya	40	F	Medicine	Primary thyroid disease	Intrinsic thyroid disease, nodular Goitre, with Retrosternal extension, Superior Vena Cava obstruction and Hyperthyroidism	clinical undergraduate	NA	Labyrinth	not cleared	English	restricted access	no	T Poulton	tpoulton@sgul.ac.uk
SGULeVI SGUL P030	Carolyn	37	F	Nursing	Cerebral palsy	Learning disability, cerebral palsy, epilepsy, treatment	clinical undergraduate	NA	Labyrinth	not cleared	English	restricted access	no	T Poulton	tpoulton@sgul.ac.uk
SGULeVI SGUL P031	Franklin	36	M	Nursing, dentistry	Learning disability	Challenging behaviour, self harm, dental problem	clinical undergraduate	NA	Labyrinth	not cleared	English	restricted access	no	T Poulton	tpoulton@sgul.ac.uk
SGULeVI SGUL P032	John	60	M	Nursing, medicine, paramedics	Chest pain	Chest pain, myocardial infarction,	clinical undergraduate	NA	Labyrinth	not cleared	English	restricted access	no	T Poulton	tpoulton@sgul.ac.uk
SGULeVI SGUL P033	Moses	32	M	Nursing, medicine	Dislocated shoulder	Dislocated shoulder, relocation, radiology	clinical undergraduate	NA	Labyrinth	not cleared	English	restricted access	no	T Poulton	tpoulton@sgul.ac.uk
SGULeVI SGUL P034	Ralph Lauren	30	M	Medicine	Insomnia and suicide	Insomnia, stress, tramezepam, suicidal behaviour	clinical undergraduate	NA	Labyrinth	not cleared	English	restricted access	no	T Poulton	tpoulton@sgul.ac.uk
SGULeVI SGUL P035	Sereena	45	F	Nursing, medicine	Downs syndrome	Down syndrome, learning disability, BMI	clinical undergraduate	NA	Labyrinth	not cleared	English	restricted access	no	T Poulton	tpoulton@sgul.ac.uk
SGULeVI SGUL P036	Jim Brown	45	M	Paramedic	Chest pain	Chest pain, emergency response, handover to hospital	clinical undergraduate	NA	Labyrinth	not cleared	English	restricted access	no	T Poulton	tpoulton@sgul.ac.uk
SGULeVI SGUL P037	Mr Jones	80	M	Medicine	Lower lobe pneumonia	chronic obstructive pulmonary disease, dementia, asthma, empysema, chronic atrial fibrillation	clinical undergraduate	NA	Labyrinth	not cleared	English	restricted access	no	T Poulton	tpoulton@sgul.ac.uk
SGULeVI SGUL P038	Reg Gutteridge	46	M	Medicine	Asthma	Bronchial constriction, causes, risk facotrs, treatment	clinical undergraduate	NA	Labyrinth	not cleared	English	restricted access	no	T Poulton	tpoulton@sgul.ac.uk
SGULeVI SGUL P039	John F	34	M	Medicine	autoimmune thyroiditis	Hashimoto's disease, hypothyroidism, thyroid antibodies	clinical undergraduate	NA	Labyrinth	not cleared	English	restricted access	no	T Poulton	tpoulton@sgul.ac.uk
SGULeVI SGUL P040	Gerry G	40	F	Medicine	autoimmune thyroiditis	Grave's disease, hyperthyroidism, thyroid antibodies	clinical undergraduate	NA	Labyrinth	not cleared	English	restricted access	no	T Poulton	tpoulton@sgul.ac.uk
SGULeVI SGUL P041	Mike E	48	M	Medicine	Aggrssive behaviour	Management of aggressive behaviour, psychiatric inpatient	clinical undergraduate	NA	Labyrinth	not cleared	English	restricted access	no	T Poulton	tpoulton@sgul.ac.uk
SGULeVI SGUL P042	Maria E	35	F	Nursing	Psychiatric inpatient, bipolar disorder	Professional boundars, and professional behaviour	clinical undergraduate	NA	Labyrinth	not cleared	English	restricted access	no	T Poulton	tpoulton@sgul.ac.uk
SGULeVI SGUL P043	Cairns			Medicine	Drugaddiction	Management of longterm cocaine addiction	clinical undergraduate	NA	Labyrinth	not cleared	English	restricted access	no	T Poulton	tpoulton@sgul.ac.uk

Ref ID	Institution	VP Title	VP Age	VP Sex	Discipline	Clinical topics	Brief description	Educational level	URL if available	VP system	IPR	Language	Access rights	Has been used by students?	Contact name	Contact email
eVIPKi1	KI	Agneta	44 F		Dentistry	Comprehensive dentistry	Seeks for complete dental treatment	Undergraduate	can be provided on request	Web-SP	Cleared	English	Restricted	y	N Zary	
eVIPKi5	KI	Bernando	51 M		Dentistry	Comprehensive dentistry	Seeks for complete dental treatment	Undergraduate	can be provided on request	Web-SP	Cleared	English	Restricted	y	N Zary	evip at patientcases.org
eVIPKi6	KI	Charlotte	62 F		Dentistry	Comprehensive dentistry	Seeks for pain in the left side of the Mandible	Undergraduate	can be provided on request	Web-SP	Cleared	English	Restricted	y	N Zary	evip at patientcases.org
eVIPKi7	KI	Gunnar	50 M		Dentistry	Comprehensive dentistry	Patient with pain in the left side of the Maxilla	Undergraduate	can be provided on request	Web-SP	Cleared	English	Restricted	y	N Zary	evip at patientcases.org
eVIPKi8	KI	Harry	76 M		Dentistry	Comprehensive dentistry	Patient with two fractured teeth in left Mandible	Undergraduate	can be provided on request	Web-SP	Cleared	English	Restricted	y	N Zary	evip at patientcases.org
eVIPKi9	KI	Henning	66 M		Dentistry	Comprehensive dentistry	Patient with bleeding gingiva and tooth loosening	Undergraduate	can be provided on request	Web-SP	Cleared	English	Restricted	y	N Zary	evip at patientcases.org
eVIPKi10	KI	Karl-Arne	44 M		Dentistry	Comprehensive dentistry	Patient that wants complete dental treatment due to overall bad dental situation	Undergraduate	can be provided on request	Web-SP	Cleared	English	Restricted	y	N Zary	evip at patientcases.org
eVIPKi11	KI	Kerstin	74 F		Dentistry	Comprehensive dentistry	Seeks for complete treatment but no urgent problems	Undergraduate	can be provided on request	Web-SP	Cleared	English	Restricted	y	N Zary	evip at patientcases.org
eVIPKi12	KI	Laila	57 F		Dentistry	Comprehensive dentistry	Patient has no acute problems. She want to look better in her mouth and lacks a numl	Undergraduate	can be provided on request	Web-SP	Cleared	English	Restricted	y	N Zary	evip at patientcases.org
eVIPKi13	KI	Marcus	28 M		Dentistry	Comprehensive dentistry	Patient with acute pain in regio 15	Undergraduate	can be provided on request	Web-SP	Cleared	English	Restricted	y	N Zary	evip at patientcases.org
eVIPKi14	KI	Margaretha	49 F		Dentistry	Comprehensive dentistry	Patient asking for treatment of pain from right upper molars	Undergraduate	can be provided on request	Web-SP	Cleared	English	Restricted	y	N Zary	evip at patientcases.org
eVIPKi15	KI	Nadja	43 F		Dentistry	Comprehensive dentistry	Patient has nu acute problems, but has not been at the dentist for a while	Undergraduate	can be provided on request	Web-SP	Cleared	English	Restricted	y	N Zary	evip at patientcases.org
eVIPKi16	KI	Pedro	41 M		Dentistry	Comprehensive dentistry	Seeks for complete treatment due to loose theets	Undergraduate	can be provided on request	Web-SP	Cleared	English	Restricted	y	N Zary	evip at patientcases.org
eVIPKi17	KI	Roland	72 M		Dentistry	Comprehensive dentistry	Patient ant a full dental treatment so he might chew better and also do something to th	Undergraduate	can be provided on request	Web-SP	Cleared	English	Restricted	y	N Zary	evip at patientcases.org
eVIPKi18	KI	Sahdo	60 M		Dentistry	Comprehensive dentistry	Patient want a full dental treatment and complains about pain from the lower right region	Undergraduate	can be provided on request	Web-SP	Cleared	English	Restricted	y	N Zary	evip at patientcases.org
eVIPKi2	KI	Betsy	57 F		Dentistry	Comprehensive dentistry	The patienten has lost a temporary construction in the upper front	Undergraduate	can be provided on request	Web-SP	Cleared	English	Restricted	y	N Zary	evip at patientcases.org
eVIPKi19	KI	Shawn M	11 M		Medicine	Medical nutrition	11 years old overweight boy	Undergraduate	can be provided on request	Web-SP	Cleared	English	Restricted	y	N Zary	evip at patientcases.org
eVIPKi20	KI	Maria S	36 F		Medicine	Medical nutrition	36 year old pregnant woman at 10 weeks gestation	Undergraduate	can be provided on request	Web-SP	Cleared	English	Restricted	y	N Zary	evip at patientcases.org
eVIPKi21	KI	Carol J	29 F		Medicine	Medical nutrition	29 year old overweight pregnant woman at 4 months gestation	Undergraduate	can be provided on request	Web-SP	Cleared	English	Restricted	y	N Zary	evip at patientcases.org
eVIPKi22	KI	Melanies M	34 F		Medicine	Medical nutrition	34 year old woman with gestational diabetes	Undergraduate	can be provided on request	Web-SP	Cleared	English	Restricted	y	N Zary	evip at patientcases.org
eVIPKi23	KI	Heather M	0.5 F		Medicine	Medical nutrition	6 month old breastfeeding infant with poor weight gain	Undergraduate	can be provided on request	Web-SP	Cleared	English	Restricted	y	N Zary	evip at patientcases.org
eVIPKi24	KI	Jose M	2 M		Medicine	Medical nutrition	2 year toddler at risk for becoming overweight with mild anemia	Undergraduate	can be provided on request	Web-SP	Cleared	English	Restricted	y	N Zary	evip at patientcases.org
eVIPKi25	KI	Erin B	15 F		Medicine	Medical nutrition	15 year old underweight girl with restrictive eating at risk for anorexia nervosa	Undergraduate	can be provided on request	Web-SP	Cleared	English	Restricted	y	N Zary	evip at patientcases.org
eVIPKi26	KI	Fred J	75 M		Medicine	Medical nutrition	75 year old man with hip fracture	Undergraduate	can be provided on request	Web-SP	Cleared	English	Restricted	y	N Zary	evip at patientcases.org
eVIPKi27	KI	Elizabeth M	65 F		Medicine	Medical nutrition	65 year old woman with hyperlipidemia	Undergraduate	can be provided on request	Web-SP	Cleared	English	Restricted	y	N Zary	evip at patientcases.org
eVIPKi28	KI	Agnes J	82 F		Medicine	Medical nutrition	82 year old underweight woman with stroke and pneumonia	Undergraduate	can be provided on request	Web-SP	Cleared	English	Restricted	y	N Zary	evip at patientcases.org
eVIPKi29	KI	Lisa C	38 F		Medicine	Medical nutrition	38 year old woman with post pregnancy obesity	Undergraduate	can be provided on request	Web-SP	Cleared	English	Restricted	y	N Zary	evip at patientcases.org
eVIPKi30	KI	Janice J	46 F		Medicine	Medical nutrition	Risk evaluation for a 30 year old overweight woman with a BMI 27 kg/m2	Undergraduate	can be provided on request	Web-SP	Cleared	English	Restricted	y	N Zary	evip at patientcases.org
eVIPKi31	KI	Tomas M	67 M		Medicine	Medical nutrition	67 year old obese man with hypertension, hyperlipidemia	Undergraduate	can be provided on request	Web-SP	Cleared	English	Restricted	y	N Zary	evip at patientcases.org
eVIPKi32	KI	William E	83 M		Medicine	Medical nutrition	83 year old man with early cardiac failure	Undergraduate	can be provided on request	Web-SP	Cleared	English	Restricted	y	N Zary	evip at patientcases.org
eVIPKi33	KI	Richard R	40 M		Medicine	Medical nutrition	40 year old man with hyperlipidemia	Undergraduate	can be provided on request	Web-SP	Cleared	English	Restricted	y	N Zary	evip at patientcases.org
eVIPKi34	KI	Sarah M	46 F		Medicine	Medical nutrition	46 year old woman with metabolic syndrome	Undergraduate	can be provided on request	Web-SP	Cleared	English	Restricted	y	N Zary	evip at patientcases.org
eVIPKi35	KI	Philip B	59 M		Medicine	Medical nutrition	59 year old man with gastroesophageal reflux disease	Undergraduate	can be provided on request	Web-SP	Cleared	English	Restricted	y	N Zary	evip at patientcases.org
eVIPKi36	KI	Grace M	45 F		Medicine	Medical nutrition	45 year old woman with type 2 diabetes	Undergraduate	can be provided on request	Web-SP	Cleared	English	Restricted	y	N Zary	evip at patientcases.org

eVIPKi37	KI	Timothy C	12 M	Medicine	Medical nutrition	12 year old boy with type 1 diabetes	Undergraduate	can be provided on request	Web-SP	Cleared	English	Restricted	y	N Zary	evip at patientcases.org
eVIPKi38	KI	William C	44 M	Medicine	Internal medicine	comes to see you because of sudden onset of weakness in his left arm and leg	Undergraduate	can be provided on request	Web-SP	Partly cleared	English	Restricted	y	N Zary	evip at patientcases.org
eVIPKi39	KI	Tamara F	36 F	Medicine	Internal medicine	comes to see you for evaluation of abdominal pain	Undergraduate	can be provided on request	Web-SP	Partly cleared	English	Restricted	y	N Zary	evip at patientcases.org
eVIPKi40	KI	Sam L	20 M	Medicine	Internal medicine	comes to see you for evaluation of a recurrent headache	Undergraduate	can be provided on request	Web-SP	Partly cleared	English	Restricted	y	N Zary	evip at patientcases.org
eVIPKi41	KI	Doris S	59 F	Medicine	Internal medicine	comes to see you for evaluation of shortness of breath	Undergraduate	can be provided on request	Web-SP	Partly cleared	English	Restricted	y	N Zary	evip at patientcases.org
eVIPKi42	KI	Devin Q	28 M	Medicine	Internal medicine	comes to see you for evaluation of back pain	Undergraduate	can be provided on request	Web-SP	Partly cleared	English	Restricted	y	N Zary	evip at patientcases.org
eVIPKi43	KI	Agneta	44 F	Dentistry	Comprehensive dentistry	Seeks for complete dental treatment	Undergraduate	can be provided on request	Web-SP	Cleared	Svenska	Restricted	y	N Zary	evip at patientcases.org
eVIPKi44	KI	Bernando	51 M	Dentistry	Comprehensive dentistry	Seeks for complete dental treatment	Undergraduate	can be provided on request	Web-SP	Cleared	Svenska	Restricted	y	N Zary	evip at patientcases.org
eVIPKi45	KI	Charlotte	62 F	Dentistry	Comprehensive dentistry	Patient has pain from left side of the mandible	Undergraduate	can be provided on request	Web-SP	Cleared	Svenska	Restricted	y	N Zary	evip at patientcases.org
eVIPKi46	KI	Gunnar	50 M	Dentistry	Comprehensive dentistry	Patient with pain in the left side of the Maxilla	Undergraduate	can be provided on request	Web-SP	Cleared	Svenska	Restricted	y	N Zary	evip at patientcases.org
eVIPKi47	KI	Harry	76 M	Dentistry	Comprehensive dentistry	Patient has fractured two teeth in left side of the lower jaw	Undergraduate	can be provided on request	Web-SP	Cleared	Svenska	Restricted	y	N Zary	evip at patientcases.org
eVIPKi48	KI	Henning	66 M	Dentistry	Comprehensive dentistry	Patient with bleeding gingiva and tooth loosening	Undergraduate	can be provided on request	Web-SP	Cleared	Svenska	Restricted	y	N Zary	evip at patientcases.org
eVIPKi49	KI	Karl-Arne	44 M	Dentistry	Comprehensive dentistry	Patient has no acute problems. He want to look better in his mouth	Undergraduate	can be provided on request	Web-SP	Cleared	Svenska	Restricted	y	N Zary	evip at patientcases.org
eVIPKi50	KI	Kerstin	74 F	Dentistry	Comprehensive dentistry	Seeks for complete dental treatment	Undergraduate	can be provided on request	Web-SP	Cleared	Svenska	Restricted	y	N Zary	evip at patientcases.org
eVIPKi51	KI	Laila	57 F	Dentistry	Comprehensive dentistry	Patient has no acute problems. She want to look better in the mouth and that somethi	Undergraduate	can be provided on request	Web-SP	Cleared	Svenska	Restricted	y	N Zary	evip at patientcases.org
eVIPKi52	KI	Marcus	28 M	Dentistry	Comprehensive dentistry	Patient with acute pain in regio 15	Undergraduate	can be provided on request	Web-SP	Cleared	Svenska	Restricted	y	N Zary	evip at patientcases.org
eVIPKi53	KI	Margaretha	49 F	Dentistry	Comprehensive dentistry	Patient asking for treatment of pain from right upper molars	Undergraduate	can be provided on request	Web-SP	Cleared	Svenska	Restricted	y	N Zary	evip at patientcases.org
eVIPKi54	KI	Nadja	43 F	Dentistry	Comprehensive dentistry	Patient has nu acute problems, but has not been at the dentist for a while	Undergraduate	can be provided on request	Web-SP	Cleared	Svenska	Restricted	y	N Zary	evip at patientcases.org
eVIPKi55	KI	Pedro	41 M	Dentistry	Comprehensive dentistry	Patient want complete dental treatment due to tooth loosening and problems chewing	Undergraduate	can be provided on request	Web-SP	Cleared	Svenska	Restricted	y	N Zary	evip at patientcases.org
eVIPKi56	KI	Roland	72 M	Dentistry	Comprehensive dentistry	Patient ant a full dental treatment so he might chew better and also do something to t	Undergraduate	can be provided on request	Web-SP	Cleared	Svenska	Restricted	y	N Zary	evip at patientcases.org
eVIPKi57	KI	Sahdo	60 M	Dentistry	Comprehensive dentistry	Patient want a complete dental treatment due to a number of resaons, among other th	Undergraduate	can be provided on request	Web-SP	Cleared	Svenska	Restricted	y	N Zary	evip at patientcases.org
eVIPKi58	KI	Betsy	57 F	Dentistry	Comprehensive dentistry	The patienten has lost a temporary construction in the upper front	Undergraduate	can be provided on request	Web-SP	Cleared	Svenska	Restricted	y	N Zary	evip at patientcases.org
eVIPKi59	KI	Agda Svensson	73 F	Medicine	Farmakoterapi	Inkommer till akuten kl 04.15 på grund av andnöd	Undergraduate	can be provided on request	Web-SP	Cleared	Svenska	Restricted	y	N Zary	evip at patientcases.org
eVIPKi60	KI	Inger Svårdh	25 F	Medicine	Farmakoterapi	Inkommer till medicin akuten då hon hittats av en korridorkamrat trött, andfådd och ej	Undergraduate	can be provided on request	Web-SP	Cleared	Svenska	Restricted	y	N Zary	evip at patientcases.org
eVIPKi61	KI	Peder Kask	36 M	Medicine	Farmakoterapi	Inkommer till medicinakuten på grund av svåra centrala bröstsmärtor	Undergraduate	can be provided on request	Web-SP	Cleared	Svenska	Restricted	y	N Zary	evip at patientcases.org
eVIPKi62	KI	Stina Lundberg	56 F	Medicine	Farmakoterapi	Ligger inne på en kardiologavdelning sedan fyra dagar då hon insjuknat i en akut hjär	Undergraduate	can be provided on request	Web-SP	Cleared	Svenska	Restricted	y	N Zary	evip at patientcases.org
eVIPKi63	KI	Kalle Svensson	2.5 M	Medicine	Pediatrics	Kommer med mamma till vårdcentralen, i famnen på mamma till synes sovande	Undergraduate	can be provided on request	Web-SP	Cleared	Svenska	Restricted	y	N Zary	evip at patientcases.org
eVIPKi64	KI	Erik	3 M	Medicine	Pediatrics	Kommer till barnakuten med sin mamma pga att han fått rikligt med blåmärken de se	Undergraduate	can be provided on request	Web-SP	Cleared	Svenska	Restricted	y	N Zary	evip at patientcases.org
eVIPKi65	KI	Anders A	43 M	Medicine	Hematologi/Coagulat	Järnbristanemi pga magsårsblödning	Undergraduate	can be provided on request	Web-SP	Partly cleared	Svenska	Restricted	y	N Zary	evip at patientcases.org
eVIPKi66	KI	Mattias F	32 M	Medicine	Hematologi/Coagulat	Kronisk lymfatisk leukemi	Undergraduate	can be provided on request	Web-SP	Partly cleared	Svenska	Restricted	y	N Zary	evip at patientcases.org
eVIPKi67	KI	Anna G	52 F	Medicine	Hematologi/Coagulat	Myelom	Undergraduate	can be provided on request	Web-SP	Partly cleared	Svenska	Restricted	y	N Zary	evip at patientcases.org
eVIPKi68	KI	Klara S	35 F	Medicine	Hematologi/Coagulat	ITP	Undergraduate	can be provided on request	Web-SP	Partly cleared	Svenska	Restricted	y	N Zary	evip at patientcases.org

eVIPKi69	KI	Alexander H	14	M	Medicine	Hematologi/Coagulat Agressiv lymfom ion	Undergraduate	can be provided on request	Web-SP	Partly cleared	Svenska	Restricted	y	N Zary	evip at patientcases.org	
eVIPKi70	KI	Torsten K	62	M	Medicine	Hematologi/Coagulat B12-brisanemi pga pernicios a ion	Undergraduate	can be provided on request	Web-SP	Partly cleared	Svenska	Restricted	y	N Zary	evip at patientcases.org	
eVIPKi71	KI	Lia B	13	F	Medicine	Hematologi/Coagulat Kronisk myeloisk leukemi ion	Undergraduate	can be provided on request	Web-SP	Partly cleared	Svenska	Restricted	y	N Zary	evip at patientcases.org	
eVIPKi72	KI	Larry S	22	M	Medicine	Internal medicine	22 year old man with leukemia	Undergraduate	can be provided on request	Web-SP	Cleared	Svenska	Restricted	y	N Zary	evip at patientcases.org
eVIPKi73	KI	Bob F	39	M	Medicine	Internal medicine		Undergraduate	can be provided on request	Web-SP	Cleared	Svenska	Restricted	y	N Zary	evip at patientcases.org
eVIPKi3	KI	Karin	59	F	Nursing	Nursing care	In på akuten kommer en kvinna som ser medtagen ut, hon har svårt att gå, måste st	Undergraduate	can be provided on request	Web-SP	Cleared	Svenska	Restricted	y	N Zary	evip at patientcases.org
eVIPKi4	KI	Annhild	86	F	Nursing	Nursing care	En kvinna kommer in med ambulans till akuten. Hittad på golvet i köket av hemtjänste	Undergraduate	can be provided on request	Web-SP	Cleared	Svenska	Restricted	y	N Zary	evip at patientcases.org
eVIPKi74	KI	Filip A	32	M	Nursing	Nursing care	Pre-operativ encounter of a young patient	Undergraduate	can be provided on request	Web-SP	Cleared	Svenska	Restricted	y	N Zary	evip at patientcases.org
eVIPKi75	KI	Filip A	32	M	Nursing	Nursing care	Post-operative encounter of a young patient	Undergraduate	can be provided on request	Web-SP	Cleared	Svenska	Restricted	y	N Zary	evip at patientcases.org
eVIPKi76	KI	Agda N	71	F	Nursing	Nursing care	Pre-operativ encounter of an old patient	Undergraduate	can be provided on request	Web-SP	Cleared	Svenska	Restricted	y	N Zary	evip at patientcases.org
eVIPKi77	KI	Agda N	71	F	Nursing	Nursing care	Post-operative encounter of an old patient	Undergraduate	can be provided on request	Web-SP	Cleared	Svenska	Restricted	y	N Zary	evip at patientcases.org
eVIPKi78	KI	Cecilia D	25	F	Nursing	Nursing care	Intox case - Patient inkommer medvetande sänkt till akuten	Undergraduate	can be provided on request	Web-SP	Cleared	Svenska	Restricted	y	N Zary	evip at patientcases.org
eVIPKi79	KI	Regina P	40	F	Medicine	Medical nutrition	40 year old woman with celiac disease	Undergraduate	can be provided on request	Web-SP	Cleared	Svenska	Restricted	y	N Zary	evip at patientcases.org
eVIPKi80	KI	Beth C	30	F	Medicine	Medical nutrition	30 year old woman with Crohn's disease / short bowel syndrome	Undergraduate	can be provided on request	Web-SP	Cleared	Svenska	Restricted	y	N Zary	evip at patientcases.org
eVIPKi81	KI	Meera S	50	F	Medicine	Medical nutrition	50 year old woman with squamous cell carcinoma of her tongue / surgical resection	Undergraduate	can be provided on request	Web-SP	Cleared	Svenska	Restricted	y	N Zary	evip at patientcases.org
eVIPKi82	KI	Viktor J	41	M	Medicine	Medical nutrition	41 year old man with brain tumor	Undergraduate	can be provided on request	Web-SP	Cleared	Svenska	Restricted	y	N Zary	evip at patientcases.org
eVIPKi83	KI	Catherine S	55	F	Medicine	Medical nutrition	55 year old woman with breast cancer	Undergraduate	can be provided on request	Web-SP	Cleared	Svenska	Restricted	y	N Zary	evip at patientcases.org
eVIPKi84	KI	Katrin G	45	F	Medicine	Medical nutrition	45 year woman with perimenopausal symptoms	Undergraduate	can be provided on request	Web-SP	Cleared	Svenska	Restricted	y	N Zary	evip at patientcases.org
eVIPKi85	KI	George A	71	M	Medicine	Medical nutrition	71 year old man with benign prostatic disease	Undergraduate	can be provided on request	Web-SP	Cleared	Svenska	Restricted	y	N Zary	evip at patientcases.org

Ref ID	Institution	VP Title	VP Age	VP Sex	Discipline e.g medicine, nursing	Clinical topics	Brief description	Educational level	URL if available	VP system	IPR (Cleared/ Partly cleared/N ot cleared)	Language	Access rights	Has been used by students ?	Contact name	Contact email
LMU		A 40-year-old engineer complaining of diminished strength, visual disturbances, and increased thirst	40 m		internal medicine	Diabete mellitus	A 40-year-old engineer complaining of diminished strength, visual disturbances, and increased thirst	undergraduate	can be provided on request	CASUS	cleared	en,de	restricted	yes (German version)	I. Hege	support@casus.net
LMU		A 47-year old female teacher with headache and fever	47 f		internal medicine	Malaria	A 47-year old female teacher with headache and fever	undergraduate	can be provided on request	CASUS	cleared	en,de	restricted	yes (German version)	I. Hege	support@casus.net
LMU		43 year old saleswoman presented with dyspnea	43 f		radiology		43 year old saleswoman presented with dyspnea	undergraduate	can be provided on request	CASUS	cleared	en,de	restricted	yes (German version)	I. Hege	support@casus.net
LMU		A 48 yr old male with severe chest pain	48 m		cardiology	Atelektasis, lung tumor Myocardial infarction	A 48 yr old male with severe chest pain	undergraduate	can be provided on request	CASUS	cleared	en,de	restricted	yes (German version)	I. Hege	support@casus.net
LMU		57 jährige Versicherungsangestellte mit Augen- und Mundtrockenheit	57 f		endocrinolog y		A 57- yr old patient complaints about dryness of eyes and mouth	undergraduate	can be provided on request	CASUS	cleared	de	restricted	yes	I. Hege	support@casus.net
LMU		Patientin mi Ikterus	58 f		gastroenterol ogy	Sjögren-Syndrome	A 58 yr old patient with jaundice	undergraduate	can be provided on request	CASUS	cleared	de	restricted	yes	I. Hege	support@casus.net
LMU		78 jährige Frau mit ausgeprägten Hämatomen	78 f		hematology	Autoimmune Hepatitis	A 78 yr old patient with multiple hematoma	undergraduate	can be provided on request	CASUS	cleared	de	restricted	yes	I. Hege	support@casus.net
LMU		72 jährige Patientin mit Pneumonie und Diarrhoen	72 f		gastroenterol ogy	Secondary Thrombocytopenia	A 72 yr old patient complaining about diarrhea	undergraduate	can be provided on request	CASUS	cleared	de	restricted	yes	I. Hege	support@casus.net
LMU		69-jährige Patientin mit Bewegungsstörungen	69 f		gastroenterol ogy	pseudomembrane Colitis chronic atrophic gastritis	A 69 yr old patient with anemia	undergraduate	can be provided on request	CASUS	cleared	de	restricted	yes	I. Hege	support@casus.net
LMU		35-jährige Patientin mit Halsschwellung	35 f		hematology/o ncology	Hodgkin-lymphoma	A 35 yr old patient complaining about jugular swelling	undergraduate	can be provided on request	CASUS	cleared	de	restricted	yes	I. Hege	support@casus.net
LMU		28 jähriger Patient mit Übelkeit, Blässe und Atemnot	28 m		nephrology	renal insufficiency	A 28 yr old patient complaining about weakness and dyspnea	undergraduate	can be provided on request	CASUS	cleared	de	restricted	yes	I. Hege	support@casus.net
LMU		54 jähriger Patient mit Kopfschmerzen	54 m		endocrinolog y	macroprolactinoma	A 54 yr old patient with headache	undergraduate	can be provided on request	CASUS	cleared	de	restricted	yes	I. Hege	support@casus.net
LMU		Schülerin mit Halsschmerzen	19 f		internal medicine	infectious mononucleosis	A 19 yr old school girl with sore throat	undergraduate	can be provided on request	CASUS	cleared	de	restricted	yes	I. Hege	support@casus.net
LMU		35 jähriger Versicherungskaufmann mit Atemnot und Fieber	35 m		cardiology	Cardial insufficiency	A 35 yr old insurance salesman with dyspnea and fever	undergraduate	can be provided on request	CASUS	cleared	de	restricted	yes	I. Hege	support@casus.net

LMU	Junger Mann mit Kreislaufkollaps	32 m	cardiology	Paroxysmal Tachycardia	A 32 yr old patient with a circulatory collapse	undergraduate	can be provided on request	CASUS	cleared	de	restricted	yes	I. Hege	support@casus.net
LMU	Bewußtlosigkeit bei einer 56-jährigen Frau	56 f	pneumology	Bronchial carcinoma	A 56 yr old patient with a syncope	undergraduate	can be provided on request	CASUS	cleared	de	restricted	yes	I. Hege	support@casus.net
LMU	Patientin mit Milzschwellung	39 f	hematology	Chronic myeloic leucemia	A 39 yr old patient with splenomegaly	undergraduate	can be provided on request	CASUS	cleared	de	restricted	yes	I. Hege	support@casus.net
LMU	Plötzliche Atemnot und Herzstolpern nach einem Motorradunfall	40 m	cardiology	Artrial fibrillation	A motorcyclist after an accident complains about dyspnea and palpitations	undergraduate	can be provided on request	CASUS	cleared	de	restricted	yes	I. Hege	support@casus.net
LMU	54-jähriger Elektriker mit Kopfschmerzen.	54 m	internal medicine	Atherosclerosis of renal artery	A 54 yr old patient with headache	undergraduate	can be provided on request	CASUS	cleared	de	restricted	yes	I. Hege	support@casus.net
LMU	61-jähriger Bauarbeiter mit Druckgefühl in der Brust	61 m	cardiology	Rheumatic Aortal valve stenosis	A 61 yr old construction worker with a syncope	undergraduate	can be provided on request	CASUS	cleared	de	restricted	yes	I. Hege	support@casus.net
LMU	Patientin mit multiplen Artefakten im Gesicht	66 f	gastroenterology	Carcinoma of the Colon	A 66 patient with anemia and skin injuries	undergraduate	can be provided on request	CASUS	cleared	de	restricted	yes	I. Hege	support@casus.net
LMU	59-jährige Patientin mit Schwindel und Gesichtsrötung	59 f	Hematology/Oncology	Polycythaemia vera	A 59 yr old patient with flush	undergraduate	can be provided on request	CASUS	cleared	de	restricted	yes	I. Hege	support@casus.net
LMU	Diffuser Gelenkschmerz	45 f	rheumatology	myalgia	A patient with articular pain	undergraduate	can be provided on request	CASUS	cleared	de	restricted	yes	I. Hege	support@casus.net
LMU	Knieschwellung	40 m	rheumatology	gout	A patient with a swollen knee	undergraduate	can be provided on request	CASUS	cleared	de	restricted	yes	I. Hege	support@casus.net
LMU	Wechselnde Schmerzen der kleinen Gelenke	45 f	rheumatology	polymyositis	A patient with joint pain	undergraduate	can be provided on request	CASUS	cleared	de	restricted	yes	I. Hege	support@casus.net
LMU	Zehenschwellung	35 f	rheumatology	psoriasis	A patient with swelling of the toes	undergraduate	can be provided on request	CASUS	cleared	de	restricted	yes	I. Hege	support@casus.net
LMU	Hüftgelenkschmerzen	75 f	rheumatology	coxarthrosis	A patient with hip pain	undergraduate	can be provided on request	CASUS	cleared	de	restricted	yes	I. Hege	support@casus.net
LMU	24-jährige Studentin mit Atemnot	24 f	radiology	pneumothorax	A 24 yr old student with dyspnea	undergraduate	can be provided on request	CASUS	cleared	de	restricted	yes	I. Hege	support@casus.net
LMU	79-jährige Rentnerin mit Schmerzen im rechten Knie	79 m	radiology	gonarthrosis	A 79 yr old patient with a knee swelling	undergraduate	can be provided on request	CASUS	cleared	de	restricted	yes	I. Hege	support@casus.net
LMU	69-jähriger Rentner mit allgemeinem Krankheitsgefühl	69 m	radiology	bronchial carcinoma	A 69 yr old patient with weight loss	undergraduate	can be provided on request	CASUS	cleared	de	restricted	yes	I. Hege	support@casus.net
LMU	33-jährige Krankenschwester mit Kreislaufkollaps	33 f	radiology	ARDS	A 33 yr old nurse with a syncope	undergraduate	can be provided on request	CASUS	cleared	de	restricted	yes	I. Hege	support@casus.net

LMU	77-jähriger Rentner mit Schwindel postoperativ	77 m	radiology	pneumonia	A 77 yr old patient with vertigo	undergraduate	can be provided on request	CASUS	cleared	de	restricted	yes	I. Hege	support@casus.net
LMU	38-jähriger Bankangestellter mit Schmerzen im linken Knie	38 m	radiology	osteomyelitis	A 38 yr old employee with pain of the left knee	undergraduate	can be provided on request	CASUS	cleared	de	restricted	yes	I. Hege	support@casus.net
LMU	37-jähriger Maler mit Schmerzen im linken Bein	37 m	radiology	fracture of the tibia	A 37 yr old painter with pain of the left leg	undergraduate	can be provided on request	CASUS	cleared	de	restricted	yes	I. Hege	support@casus.net
LMU	Adipositas		endocrinology	adipositas	3 key-feature cases about adipositas	CME	can be provided on request	CASUS	cleared	de	restricted	yes	I. Hege	support@casus.net
LMU	hypertonia		internal medicine	hypertonia	6 key-feature cases about hypertonia	CME	can be provided on request	CASUS	cleared	de	restricted	yes	I. Hege	support@casus.net
LMU	Diabetes		endocrinology	diabetes	3 key-feature cases about diabetes in general	CME	can be provided on request	CASUS	cleared	de	restricted	yes	I. Hege	support@casus.net
LMU	Diabetic foot syndrome		endocrinology	diabetes	3 key-feature cases about the diabetic foot syndrome	CME	can be provided on request	CASUS	cleared	de	restricted	yes	I. Hege	support@casus.net
LMU	Hypophysenerkrankungen		endocrinology	Diseases of the pituitary gland	3 key-feature cases about diseases of the pituitary gland	CME	can be provided on request	CASUS	cleared	de	restricted	yes	I. Hege	support@casus.net
LMU	Insulintherapie		endocrinology	Insulin therapy	3 key-feature cases about insulin therapy	CME	can be provided on request	CASUS	cleared	de	restricted	yes	I. Hege	support@casus.net
LMU	Nebennierenzufallstumor		endocrinology	adrenal tumor	2 key-feature cases about adrenal tumor	CME	can be provided on request	CASUS	cleared	de	restricted	yes	I. Hege	support@casus.net
LMU	Osteoporose		endocrinology	osteoporosis	2 key-feature cases about osteoporosis	CME	can be provided on request	CASUS	cleared	de	restricted	yes	I. Hege	support@casus.net
LMU	Gewichtsverlust bei einem 73-jährigen Mann	73 m	internal medicine	bronchial carcinoma	A 73 yr old patient with weight loss and back pain	undergraduate	can be provided on request	CASUS	cleared	de	restricted	yes	I. Hege	support@casus.net
LMU	Akuter Schmerz bei einem 37-jährigen Mann	37 m	internal medicine	renal calculus	A 37 yr old patient with pain	undergraduate	can be provided on request	CASUS	cleared	de	restricted	yes	I. Hege	support@casus.net
LMU	61jähriger Patient mit massiven Bauchschmerzen	61 f	gastroenterology	Colon carcinoma	A 61 yr old patient with abdominal apain	undergraduate	can be provided on request	CASUS	cleared	de	restricted	yes	I. Hege	support@casus.net
LMU	52jähriger Patient mit Sodbrennen	52 m	gastroenterology	gastro-oesophageal reflux	A 52 yr old patient with pyrosis	undergraduate	can be provided on request	CASUS	cleared	de	restricted	yes	I. Hege	support@casus.net
LMU	24jährige Patientin mit blutigen Diarrhoen	24 f	gastroenterology	Colitis ulcerosa	A 24 yr old patient with diarrhea	undergraduate	can be provided on request	CASUS	cleared	de	restricted	yes	I. Hege	support@casus.net
LMU	Mitte 30 jähriger Patient mit Oberbauchbeschwerden	35 m	gastroenterology	Dyspepsia	A 35 yr old patient with abdominal pain	undergraduate	can be provided on request	CASUS	not cleared	de	restricted	yes	I. Hege	support@casus.net

LMU	Patientin mit Oberbauchbeschwerden und Übelkeit	f	gastroenterology	chronic pancreatitis	Patient with abdominal pain and nausea	undergraduate	can be provided on request	CASUS	cleared	de	restricted	yes	I. Hege	support@casus.net
LMU	21-jähriger Patient mit Diarrhoe	21 m	gastroenterology	celiac disease	A 21 yr old patient with diarrhea	undergraduate	can be provided on request	CASUS	cleared	de	restricted	yes	I. Hege	support@casus.net
LMU	Junge Patientin mit Kopfschmerzen	30 f	neurology	cluster headache	young patient complaining about headache	undergraduate	can be provided on request	CASUS	cleared	de	restricted	yes	I. Hege	support@casus.net
LMU	Frische Luft für Herrn Nelson	63 m	pneumology	COPD	Patient with dyspnea	undergraduate	can be provided on request	CASUS	cleared	de	restricted	yes	I. Hege	support@casus.net
LMU	A 23 yr old medical student in bike accident with bus	23 m	traumatology	rupture of the spleen	A 23 yr old medical student in bike accident with bus	undergraduate	can be provided on request	CASUS	cleared	en,de	restricted	no	I. Hege	support@casus.net
LMU	Gastrale Schmerzen bei einer 62-jährigen Patientin	62 f	gastroenterology	ulcus duodeni	A 62 yr old patient with abdominal pain	undergraduate	can be provided on request	CASUS	cleared	de	restricted	yes	I. Hege	support@casus.net
LMU	Der Umzug - Augenproblematik		ophthalmology	iritocyclitis		undergraduate	can be provided on request	CASUS	cleared	de	restricted	no	I. Hege	support@casus.net
LMU	30-jähriger Patient mit hohem Blutzucker	30 m	endocrinology	acromegaly	A 30 yr old patient with hyperglucosis	undergraduate	can be provided on request	CASUS	cleared	de	restricted	yes	I. Hege	support@casus.net
LMU	35-jährige Patientin mit postpartalem Herzklopfen	35 f	endocrinology	thyroiditis	A 35 yr old patient with palpitations postpartum	undergraduate	can be provided on request	CASUS	cleared	de	restricted	yes	I. Hege	support@casus.net
LMU	21-jähriger Patient mit Tachykardie und Muskelschwäche	21 m	endocrinology	hyperthyroiditis	A 21 yr old patient with tachycardia and weakness	undergraduate	can be provided on request	CASUS	cleared	de	restricted	yes	I. Hege	support@casus.net
LMU	76-jährige Patientin mit Hyperglykämie und Hypokaliämie	76 f	endocrinology	Morbus Cushing	A 76 yr old patient with hyperglycemia and hypocal	undergraduate	can be provided on request	CASUS	cleared	de	restricted	yes	I. Hege	support@casus.net
LMU	33-jährige Patientin mit Gewichtszunahme	33 f	endocrinology	Cushing syndrome with ectopic cause	33 yr old patient with weight gain	undergraduate	can be provided on request	CASUS	cleared	de	restricted	yes	I. Hege	support@casus.net
LMU	43-jährige Patientin mit Epistaxis	43 f	endocrinology	primary hyperaldosteronism	A 43 yr old patient with epistaxis	undergraduate	can be provided on request	CASUS	cleared	de	restricted	yes	I. Hege	support@casus.net
LMU	60-jährige Patientin mit Schwäche, Magen- und Knochenschmerzen	69 f	endocrinology	primary hyperparathyroidism	A 60 yr old patient with weakness abdominal pain and ostealgia	undergraduate	can be provided on request	CASUS	cleared	de	restricted	yes	I. Hege	support@casus.net
LMU	16-jährige Patientin mit vermehrter Behaarung	16 f	endocrinology	Adrenogenital disorder	A 16 yr old patient with increased hair-growth	undergraduate	can be provided on request	CASUS	cleared	de	restricted	yes	I. Hege	support@casus.net
LMU	70-jährige Patientin mit Schwindel/Synkope	70 f	endocrinology	pancreatic benign tumor	A 70 yr old patient with vertigo and syncope	undergraduate	can be provided on request	CASUS	cleared	de	restricted	yes	I. Hege	support@casus.net
LMU	45-jährige Hausfrau mit Herzerkrankung...	45 f	endocrinology	hyperthyreosis	A 45 yr old patient with palpitations and tachycardia	undergraduate	can be provided on request	CASUS	cleared	de	restricted	yes	I. Hege	support@casus.net

LMU	Zahnarzt mit Ikterus	52	internal medicine	hepatitis E	A dentist with jaundice	undergraduate	can be provided on request	CASUS	cleared	de	restricted	yes	I. Hege	support@casus.net
LMU	Schilddrüse		internal medicine	disorders of the thyroid gland	key-feature cases about disorders of the thyroid gland	CME	can be provided on request	CASUS	cleared	de	restricted	yes	I. Hege	support@casus.net
LMU	Dyspnoe bei einer 79-jährigen Frau	79 f	internal medicine	Lack of Vitamine B12	A 79 yr old patient with dyspnea	undergraduate	can be provided on request	CASUS	cleared	de	restricted	yes	I. Hege	support@casus.net
LMU	Interkulturelles Basiswissen für Ärzte		intercultural aspects	intercultural aspects		undergraduate	can be provided on request	CASUS	not cleared	de	restricted	no	I. Hege	support@casus.net
LMU	6-monatiger Säugling mit rezidivierendem Erbrechen	6 months	pediatrics	glycogen accumulation disease (Morbus van Gierke)	A 6 month old baby with vomiting	undergraduate	can be provided on request	CASUS	not cleared	de	restricted	yes	I. Hege	support@casus.net
LMU	2-jähriger Junge mit Erbrechen	2 m	pediatrics		A 2 year old boy with vomiting	undergraduate	can be provided on request	CASUS	not cleared	de	restricted	yes	I. Hege	support@casus.net
LMU	Säugling mit Fieber	<1 f	pediatrics	AGS Obstructive Uropathy and Refluxuopathy	A baby with fever	undergraduate	can be provided on request	CASUS	not cleared	de	restricted	yes	I. Hege	support@casus.net
LMU	Der Kuss	3 f	pediatrics	Cystic fibrosis	A 3 yr old girl with diarrhea and pulmonary infections	undergraduate	can be provided on request	CASUS	not cleared	de	restricted	yes	I. Hege	support@casus.net
LMU	Moritz kleiner Fehler	m	pediatrics	Heart deformity	A boy with dsypnea and growth disorder	undergraduate	can be provided on request	CASUS	not cleared	de	restricted	yes	I. Hege	support@casus.net
LMU	78-jähriger Rentner mit Heiserkeit und Schluckbeschwerden	78 m	pneumology	tuberculosis	A 78 yr old patient with hoarsness	undergraduate	can be provided on request	CASUS	not cleared	de	restricted	yes	I. Hege	support@casus.net
LMU	66-jährige Hausfrau mit Fieber und Dyspnoe	66 f	pneumology	pneumonia	A 66 yr old patient with fever and dyspnea	undergraduate	can be provided on request	CASUS	not cleared	de	restricted	yes	I. Hege	support@casus.net
LMU	13-jähriges Mädchen mit Schmerzen in den Sprunggelenken	13 f	radiology	Enchondromatosis	A 13 yr old girl with pain of the lower legs	undergraduate	can be provided on request	CASUS	cleared	de	restricted	yes	I. Hege	support@casus.net
LMU	12-jähriges Mädchen mit Schwellung am rechten Knie	12 f	radiology	Osteosarcoma	A 12 yr old girl with swelling of the right knee	undergraduate	can be provided on request	CASUS	cleared	de	restricted	yes	I. Hege	support@casus.net
LMU	17 year old soccer player	17 m	emergency medicine	Fracture of the tibia	17 year old soccer player	undergraduate	can be provided on request	CASUS	cleared	en	restricted	yes	I. Hege	support@casus.net
LMU	19 yr old girl in severe auto accident	19 f	emergency medicine	Polytrauma	19 yr old girl in severe auto accident	undergraduate	can be provided on request	CASUS	cleared	en	restricted	yes	I. Hege	support@casus.net
LMU	Markus Meier - fall from a ladder	m	emergency medicine	Fracture of the femur	Markus Meier - fall from a ladder	undergraduate	can be provided on request	CASUS	cleared	en	restricted	yes	I. Hege	support@casus.net
LMU	65 jähriger Patient mit Sehstörungen	65 m	neurology	Stenosis of the A. carotis	A 65 yr old patient with visual impaired vision	undergraduate	can be provided on request	CASUS	not cleared	de	restricted	yes	I. Hege	support@casus.net

LMU	30 jährige Patientin mit Taubheitsgefühl in der Hand	30 f	neurology	carpal canal syndrome	A 30 yr old patient with numbness of the hand	undergraduate	can be provided on request	CASUS	not cleared	de	restricted	yes	I. Hege	support@casus.net
LMU	Kopfschmerzen bei einer 71-jährigen Frau	71 f	neurology	subarachnoidal bleeding	A 71 yr old patient with headache	undergraduate	can be provided on request	CASUS	cleared	de	restricted	yes	I. Hege	support@casus.net

Ref ID	Institution	VP Title	VP Age	VP Sex	Discipline e.g. medicine, nursing	Clinical topics	Brief description	Educational level	URL if available	VP system	IPR (Cleared/Partly cleared/N)	Language	Access rights	Has been used by students	Contact name	Contact email
	Warwick/IVIMEDS	Achilles Tyropolis	45	Male	Medicine	Achilles tendon tear	While playing volleyball, Achilles Tyropolis, 45, heard a pop, felt extreme pain in the back of his left leg, and couldn't walk.	Undergraduate	Upon request	IVIMEDS	Cleared for use within IVIMEDS	English	Restricted to IVIMEDS partners	Yes	Dr David A Davies	david.davies@warwick.ac.uk
	Warwick/IVIMEDS	Albert Lewis	70	Male	Medicine	Asbestosis	Albert Lewis, 70, is a retired shipyard worker who has become progressively short of breath. He is a smoker.	Undergraduate	Upon request	IVIMEDS	Cleared for use within IVIMEDS	English	Restricted to IVIMEDS partners	Yes	Dr David A Davies	david.davies@warwick.ac.uk
	Warwick/IVIMEDS	Alisyn Smith	0	Female	Medicine	Premature birth	Alisyn Smith, newborn, is born at a gestational age of 32. She is initially depressed at birth, but recovers. She has a persistently open patent ductus arteriosus, but it eventually closes during the second day of life.	Undergraduate	Upon request	IVIMEDS	Cleared for use within IVIMEDS	English	Restricted to IVIMEDS partners	Yes	Dr David A Davies	david.davies@warwick.ac.uk
	Warwick/IVIMEDS	Anabela Faria	80	Female	Medicine	Subdural hematoma	Anabela Faria, 80 y.o., slipped at home and hit her head yesterday. Today, she has an increasing headache and excessive somnolence.	Undergraduate	Upon request	IVIMEDS	Cleared for use within IVIMEDS	English	Restricted to IVIMEDS partners	Yes	Dr David A Davies	david.davies@warwick.ac.uk
	Warwick/IVIMEDS	Deborah Jones	10	Female	Medicine	Normal sexual development	Debbie Jones, 10, is brought in by her mother who is concerned about what she regards as premature sexual development in Debbie, specifically, breast development.	Undergraduate	Upon request	IVIMEDS	Cleared for use within IVIMEDS	English	Restricted to IVIMEDS partners	Yes	Dr David A Davies	david.davies@warwick.ac.uk
	Warwick/IVIMEDS	Elizabeth Hartz	77	Female	Medicine	Congestive heart failure	Elizabeth Hartz, 77, has long-standing hypertensive heart disease and congestive heart failure.	Undergraduate	Upon request	IVIMEDS	Cleared for use within IVIMEDS	English	Restricted to IVIMEDS partners	Yes	Dr David A Davies	david.davies@warwick.ac.uk
	Warwick/IVIMEDS	Eunice Stafford	42	Female	Medicine	Pap smear	Eunice Stafford, 42, comes in for her regular Pap smear. Everything appears fine.	Undergraduate	Upon request	IVIMEDS	Cleared for use within IVIMEDS	English	Restricted to IVIMEDS partners	Yes	Dr David A Davies	david.davies@warwick.ac.uk
	Warwick/IVIMEDS	Fannie Farmer	82	Female	Medicine	Hip fracture, osteoporosis	Sarah Farmer, 82, grandmother of George Farmer, fell at home and broke her hip. She has advanced osteoporosis. She also has extensive osteoarthritis.	Undergraduate	Upon request	IVIMEDS	Cleared for use within IVIMEDS	English	Restricted to IVIMEDS partners	Yes	Dr David A Davies	david.davies@warwick.ac.uk
	Warwick/IVIMEDS	George Farmer	33	Male	Medicine	Puncture Wound	George Farmer, 33, has a puncture wound to his leg that has become infected (cellulitis). He is past due for a tetanus booster.	Undergraduate	Upon request	IVIMEDS	Cleared for use within IVIMEDS	English	Restricted to IVIMEDS partners	Yes	Dr David A Davies	david.davies@warwick.ac.uk
	Warwick/IVIMEDS	Helen Cushing	47	Female	Medicine	Cushing Syndrome	Helen Cushing, 47, complains of feeling weak, easily tired, and gaining weight. Further testing indicate that she has Cushing Disease.	Undergraduate	Upon request	IVIMEDS	Cleared for use within IVIMEDS	English	Restricted to IVIMEDS partners	Yes	Dr David A Davies	david.davies@warwick.ac.uk
	Warwick/IVIMEDS	Jennifer Pinrod	28	Female	Medicine	PID	Jennifer Pinrod, 28, complains of pelvic pain and fever.	Undergraduate	Upon request	IVIMEDS	Cleared for use within IVIMEDS	English	Restricted to IVIMEDS partners	Yes	Dr David A Davies	david.davies@warwick.ac.uk

Warwick/IVIMEDS Jessyca Smith	16 Female	Medicine	Pregnancy	Jessyca Smith, 16, daughter of Joan and John Smith, is 6 wks. late for her period. A home pregnancy test was positive. She didn't want to become pregnant. She has used marijuana, tobacco, and cocaine on an occasion basis and is concerned about the effects on the fetus. She is considering an abortion, but ultimately decides to keep the pregnancy.	Undergraduate	Upon request	IVIMEDS	Cleared for use within IVIMEDS partners	English	Restricted to IVIMEDS partners	Yes	Dr David A Davies	david.davies@warwick.ac.uk
Warwick/IVIMEDS Lester Toosie	71 Male	Medicine	TIA	Lester Toosie, 71, experienced a sudden loss of vision in one eye that resolved in about half an hour.	Undergraduate	Upon request	IVIMEDS	Cleared for use within IVIMEDS	English	Restricted to IVIMEDS partners	Yes	Dr David A Davies	david.davies@warwick.ac.uk
Warwick/IVIMEDS Louis Marlboro	68 Male	Medicine	COPD	Louis Marlboro, 68, has chronic bronchitis and emphysema from smoking who experiences an acute exacerbation.	Undergraduate	Upon request	IVIMEDS	Cleared for use within IVIMEDS	English	Restricted to IVIMEDS partners	Yes	Dr David A Davies	david.davies@warwick.ac.uk
Warwick/IVIMEDS Manuel Faria	81 Male	Medicine	Hypertension	Manuel Faria, 81 y.o., has high blood pressure that is difficult to control.	Undergraduate	Upon request	IVIMEDS	Cleared for use within IVIMEDS	English	Restricted to IVIMEDS partners	Yes	Dr David A Davies	david.davies@warwick.ac.uk
Warwick/IVIMEDS Mark Finn	28 Male	Medicine	Chest pain	Mark Finn, 28, experiences chest pain with exertion (swimming). He's worried that he has heart disease. (His father died of a heart attack.) It turns out to be due to muscle strain and overuse.	Undergraduate	Upon request	IVIMEDS	Cleared for use within IVIMEDS	English	Restricted to IVIMEDS partners	Yes	Dr David A Davies	david.davies@warwick.ac.uk
Warwick/IVIMEDS Martin Turner	23 Male	Medicine	Infertility	Martin Turner, 23, and his wife Mary, 22, have been trying unsuccessfully to have a baby. Martin made an appointment for himself because a friend told him that the male partner needed to be assessed first. A varicocele is noted on physical.	Undergraduate	Upon request	IVIMEDS	Cleared for use within IVIMEDS	English	Restricted to IVIMEDS partners	Yes	Dr David A Davies	david.davies@warwick.ac.uk
Warwick/IVIMEDS Mary Leiden	31 Female	Medicine	Pulmonary embolism	Mary Leiden, 31, was in the hospital for an appendectomy when she developed shortness of breath from a pulmonary embolism. Further testing reveals that she has Factor V Leiden.	Undergraduate	Upon request	IVIMEDS	Cleared for use within IVIMEDS	English	Restricted to IVIMEDS partners	Yes	Dr David A Davies	david.davies@warwick.ac.uk
Warwick/IVIMEDS Mary Turner	22 Female	Medicine	Polycystic Ovarian Syndrome	Mary Turner, 22, is seen for infertility after her husband's sperm count results was found to be normal.	Undergraduate	Upon request	IVIMEDS	Cleared for use within IVIMEDS	English	Restricted to IVIMEDS partners	Yes	Dr David A Davies	david.davies@warwick.ac.uk
Warwick/IVIMEDS Naomi Nighthawk	93 Female	Medicine	Malnutrition	Naomi Nighthawk is a 93-year-old woman who has been slowly losing weight. Her daughter knows that her mother is nearing the end of her life, but wants to be sure she is getting the proper nutrition. Office hematocrit (34) shows the patient has moderate anemia.	Undergraduate	Upon request	IVIMEDS	Cleared for use within IVIMEDS partners	English	Restricted to IVIMEDS partners	Yes	Dr David A Davies	david.davies@warwick.ac.uk
Warwick/IVIMEDS Saori Hashimoto	48 Female	Medicine	Hypothyroidism	Saori Hashimoto, 48, has experienced a gradual weight gain despite her attempts to restrict her diet. She also complains of fatigue and cold intolerance.	Undergraduate	Upon request	IVIMEDS	Cleared for use within IVIMEDS	English	Restricted to IVIMEDS partners	Yes	Dr David A Davies	david.davies@warwick.ac.uk
Warwick/IVIMEDS Shireen Hussein	15 Female	Medicine	Contraception	Shireen Hussein, 15, comes to see you for oral contraceptives. She doesn't want her parents to know, who are also your patients.	Undergraduate	Upon request	IVIMEDS	Cleared for use within IVIMEDS	English	Restricted to IVIMEDS partners	Yes	Dr David A Davies	david.davies@warwick.ac.uk
Warwick/IVIMEDS Suzie Kew	5 Female	Medicine	Heart murmur	Suzie Kew is in for a preschool physical and is noted to have a heart murmur.	Undergraduate	Upon request	IVIMEDS	Cleared for use within IVIMEDS	English	Restricted to IVIMEDS partners	Yes	Dr David A Davies	david.davies@warwick.ac.uk

Warwick/IVIMEDS Sylvia Salowitz	39 Female	Medicine	Breast cancer screening	Sylvia Salowitz, 39, mother of Sheldon, is concerned because her 60-y.o. mother has just been diagnosed with breast cancer. She wonders if she should have the genetic test and mammography.	Undergraduate	Upon request	IVIMEDS	Cleared for use within IVIMEDS	English	Restricted to IVIMEDS partners	Yes	Dr David A Davies	david.davies@warwick.ac.uk
Warwick/IVIMEDS Yevgenia Cassidy	55 Female	Medicine	Loss of libido	Yevgenia Cassidy, 55, wife of Yuri, has noticed difficulty in sexual arousal and lessening of sexual interest since menopause.	Undergraduate	Upon request	IVIMEDS	Cleared for use within IVIMEDS	English	Restricted to IVIMEDS partners	Yes	Dr David A Davies	david.davies@warwick.ac.uk
Warwick/IVIMEDS William Blake	58 Male	Medicine	Hypertension		Undergraduate	Upon request	IVIMEDS	Cleared for use within IVIMEDS	English	Restricted to IVIMEDS partners	Yes	Dr David A Davies	david.davies@warwick.ac.uk
Warwick/IVIMEDS Claire Louise Chanel	18 Female	Medicine	Cystic fibrosis	Claire is aged 22 years. She is being treated at a cystic fibrosis centre and has had three admissions to hospital over four years for infections.	Undergraduate	Upon request	IVIMEDS	Cleared for use within IVIMEDS	English	Restricted to IVIMEDS partners	Yes	Dr David A Davies	david.davies@warwick.ac.uk
Warwick/IVIMEDS Christopher Hughs	19 Male	Medicine	Smoke inhalation	Mr Hughes, a 19 year old student, is brought into A&E by ambulance following a house fire.	Undergraduate	Upon request	IVIMEDS	Cleared for use within IVIMEDS	English	Restricted to IVIMEDS partners	Yes	Dr David A Davies	david.davies@warwick.ac.uk
Warwick/IVIMEDS Elizabeth Worth	60 Female	Medicine	Breathlessness	Mrs Worth is an overweight woman who was admitted to A&E after experiencing an increasing shortness of breath and also chest pain for two days.	Undergraduate	Upon request	IVIMEDS	Cleared for use within IVIMEDS	English	Restricted to IVIMEDS partners	Yes	Dr David A Davies	david.davies@warwick.ac.uk
Warwick/IVIMEDS Hilary Hastings	15 Female	Medicine	Asthma	Severe sudden onset shortness of breath	Undergraduate	Upon request	IVIMEDS	Cleared for use within IVIMEDS	English	Restricted to IVIMEDS partners	Yes	Dr David A Davies	david.davies@warwick.ac.uk

Ref ID	Institution	VP Title	VP Age	VP Sex	Discipline e.g medicine, nursing	Clinical topics	Brief description	Education level	URL if available	VP system	IPR (Cleared/Partly cleared/Not cleared)	Language	Access rights	Has been used by students?	Contact name	Contact email
M001	UM	Elderly man with itching	65	male	Medicine: Internal medicine - Oncology	Hodgkin's disease	65 yr old man with chronic itching which recently increased. Combined with (sub) fibrile temperatures, abdominal complaints, anorexia, weight loss and microcytic anemia. First misinterpreted as an infectious cause (chronic gastritis) and later diagnosed as Hodgkin's disease.	Undergraduate		CAMPUS-Classic	partly cleared	English	restricted	yes	Bas de Leng	b.deleng@educ.unimaas.nl
M002	UM	Elderly with anemia	75	male	Medicine: Internal medicine - Oncology	Colon carcinoma, obstructive ileus	75 yr old man with asymptomatic iron deficiency anemia mistreated with iron therapy and developing an obstructive ileus caused by a colon carcinoma	Undergraduate		CAMPUS-Classic, -Card	partly cleared	English	restricted	yes	Bas de Leng	b.deleng@educ.unimaas.nl
M003	UM	Elderly male with heart murmur	70	male	Medicine: Internal medicine - Cardiology	Aortic stenosis, heart failure	70 yr old man who failed to comply with follow-up control after the diagnosis of aortic stenosis and has developed a mitral insufficiency and combined left and right ventricular failure	Undergraduate		CAMPUS-Classic	partly cleared	English	restricted	yes	Bas de Leng	b.deleng@educ.unimaas.nl
M004	UM	Young man with chest pain	24	male	Medicine: Internal medicine - Pneumology	Pneumothorax	24 yr old man with spontaneous pneumothorax of the apex of the lung without haemodynamic instability and respiratory insufficiency	Undergraduate		CAMPUS-Classic	partly cleared	English	restricted	yes	Bas de Leng	b.deleng@educ.unimaas.nl
M005	UM	Elderly woman with swollen ankles and dyspnea	61	female	Medicine: Internal medicine - Cardiology	Chronic bronchitis, heart failure	61 yr old women with emphysema who has developed a cor pulmonale with atrial fibrillation	Undergraduate		CAMPUS-Classic	partly cleared	English	restricted	yes	Bas de Leng	b.deleng@educ.unimaas.nl
H006	UM	Het spugende kind	1	male	Medicine: Pediatrics - Metabolic diseases	Hereditary Fructosis intolerance	Hereditary Fructosis intolerance	Undergraduate		CAMPUS-Classic	partly cleared	Dutch	restricted	yes	Bas de Leng	b.deleng@educ.unimaas.nl
H007	UM	Kind met hoofdpijn en misselijkheid	10	male	Medicine: Pediatrics - Neurology / Infectiology	Neuroborreliosis, differential diagnoses of Meningitis	Neuroborreliosis	Undergraduate		CAMPUS-Classic, -Card	partly cleared	Dutch	restricted	yes	Bas de Leng	b.deleng@educ.unimaas.nl
H008	UM	Kind met koorts	6	male	Medicine: Microbiology/Infectiology - Infectiology	Typhoid fever	6 yr old boy fever up to 40°C since a week.	Undergraduate		CAMPUS-Classic	partly cleared	Dutch	restricted	yes	Bas de Leng	b.deleng@educ.unimaas.nl
H009	UM	Kind met achterblijvende groei	10	female	Medicine: Pediatrics - Endocrinology	Hashimoto thyroiditis; differential diagnoses of failure to thrive, hypothyreosis	10 yr old girl with less than normal gain in length and weight the last few years.	Undergraduate		CAMPUS-Classic	partly cleared	Dutch	restricted	yes	Bas de Leng	b.deleng@educ.unimaas.nl
H010	UM	Een kind met buikpijn en koorts	3	male	Medicine: Pediatrics - Pneumology	Pneumonia	3 yr old boy with abdominal pain and fever	Undergraduate		CAMPUS-Classic	partly cleared	Dutch	restricted	yes	Bas de Leng	b.deleng@educ.unimaas.nl

VP Age	VP Sex	Discipline e.g medicine, nursing	Clinical topics	Brief description	Educational level	URL if available	VP system	IPR	Language	Access rights	Has been used by students?	Contact name	Contact email
0.0	male	Medicine: Pediatrics - Neonatology	Respiratory distress of the newborn, differential diagnosis pneumonia	At a perinatal facility you see a newborn immediately after caesarean section.	Undergraduate	-	CAMPUS-Classic	partly cleared	German	restricted	yes	Sören Huwendiek	soeren.huwendiek@med.uni-heidelberg.de
0.0	male	Medicine: Pediatrics - Metabolic diseases	Phenylketonuria of the mother	A two-day-old newborn with precarious findings is transferred from the gynecological clinic to pediatric clinic.	Undergraduate	-	CAMPUS-Classic	partly cleared	German	restricted	yes	Sören Huwendiek	soeren.huwendiek@med.uni-heidelberg.de
0.0	female	Medicine: Pediatrics - Cardiology	Congenital heart defects, ventricular septal defect, differential diagnoses of systolic murmur	3-day-old Sandra is presented in the pediatric cardiologic outpatient clinic after an abnormal ultrasound exam.	Undergraduate	-	CAMPUS-Classic	partly cleared	German	restricted	yes	Sören Huwendiek	soeren.huwendiek@med.uni-heidelberg.de
0.0	male	Medicine: Pediatrics - Neonatology / Neuro	Seizure of a newborn	4-day-old Philip is brought by ambulance to the pediatric outpatient clinic after having jerked with all extremities and lying atonic afterwards.	Undergraduate	-	CAMPUS-Classic	partly cleared	German	restricted	yes	Sören Huwendiek	soeren.huwendiek@med.uni-heidelberg.de
0.0	male	Medicine: Pediatrics - Neonatology	Differential diagnosis of jaundice in newborns, Rh hemolytic disease	5-day-old Richard has developed jaundice, he is floppy and not drinking well.	Undergraduate	-	CAMPUS-Classic	partly cleared	German	restricted	yes	Sören Huwendiek	soeren.huwendiek@med.uni-heidelberg.de
0.0	male	Medicine: Pediatrics - Metabolic diseases	Galactosemia	6-day-old Franz is presented at night time in the emergency outpatient department. He is vomiting, not drinking, lethargic and has a yellowish skin colour.	Undergraduate	-	CAMPUS-Classic	partly cleared	German	restricted	yes	Sören Huwendiek	soeren.huwendiek@med.uni-heidelberg.de
0.0	male	Medicine: Pediatrics - Nephrology / General Pediatrics	Diabetes insipidus	10-day-old Murat is presented in the pediatric outpatient clinic, he has been crying constantly and is having fever.	Undergraduate	-	CAMPUS-Classic	partly cleared	German	restricted	yes	Sören Huwendiek	soeren.huwendiek@med.uni-heidelberg.de
0.1	male	Medicine: Pediatrics - Endocrinology	Congenital adrenal hyperplasia, differential diagnoses of dehydration	The clearly dystrophic 26-day-old Fabian is seen in the pediatric outpatient clinic for vomiting and dehydration.	Undergraduate	-	CAMPUS-Classic	partly cleared	German	restricted	yes	Sören Huwendiek	soeren.huwendiek@med.uni-heidelberg.de
0.1	male	Medicine: Pediatrics - Cardiology	Tetralogy of Fallot, differential diagnoses and treatment of cyanosis	In the pediatric outpatient clinic the mother presents 5-week-old Sebastian because he develops blue lips when crying.	Undergraduate	-	CAMPUS-Classic	partly cleared	German	restricted	yes	Sören Huwendiek	soeren.huwendiek@med.uni-heidelberg.de

0.1 male	Medicine: Pediatrics - Neonatology / Gastro	Pyloric stenosis; differential diagnoses and treatment of a vomiting infant	In the pediatric outpatient clinic: Lars, 7-week- old, has been vomiting for 5 days.	Undergraduate	http://galaxy. mi.hs- heilbronn.de: 3333/myzms/ content/e54/e 351/e372/ind ex_ger.html	CAMPUS- Classic	partly cleared	German	open	yes	Sören Huwendiek	soeren.huwendiek@med.uni-heidelberg.de
0.2 male	Medicine: Pediatrics - Gastroenterology / General Pediatrics	Cow's milk allergy; differential diagnoses of gastrointestinal bleeding in infants	12-week-old Lars has been having blood in his stools for 4 weeks and is presented in the pediatric outpatient clinic by his mother.	Undergraduate	-	CAMPUS- Classic	partly cleared	German	restricted	yes	Sören Huwendiek	soeren.huwendiek@med.uni-heidelberg.de
0.4 female	Medicine: Pediatrics - Neurology	Bacterial meningitis; procedures with suspected meningitis; differential diagnoses: pneumonia, urinary tract infection	5-month-old Katrin is brought to the pediatric outpatient clinic, she has been having fever for 2 days is increasingly floppy.	Undergraduate	http://galaxy. mi.hs- heilbronn.de: 3333/myzms/ content/e54/e 351/e372/ind ex_ger.html	CAMPUS- Classic, - Card	partly cleared	German	open	yes	Sören Huwendiek	soeren.huwendiek@med.uni-heidelberg.de
0.5 male	Medicine: Pediatrics - Infectiology	Waterhouse-Friderichsen- Syndrome	6-month-old infant, treated with Paracetamol for high fever the night before, is now presented in the pediatric clinic for having developed bruises over night.	Undergraduate	-	CAMPUS- Classic	partly cleared	German	restricted	yes	Sören Huwendiek	soeren.huwendiek@med.uni-heidelberg.de
0.7 female	Medicine: Pediatrics - Neurology	Hydrocephalus occlusus with aqueduct stenosis	You are a pediatrician in private practice and see 8-month-old nadja for a routine check-up.	Undergraduate	-	CAMPUS- Classic	partly cleared	German	restricted	yes	Sören Huwendiek	soeren.huwendiek@med.uni-heidelberg.de
0.7 male	Medicine: Pediatrics - Metabolic diseases	Medium-chain-acyl-CoA dehydrogenase (MCAD) deficiency	9-month-old Rainer is brought to the clinic at night. He was found lying apathetically in his bed after having had diarrhea and vomited for half a day.	Undergraduate	-	CAMPUS- Classic	partly cleared	German	restricted	yes	Sören Huwendiek	soeren.huwendiek@med.uni-heidelberg.de
0.9 male	Medicine: Pediatrics - Nephrology / General Pediatrics	Urinary tract infection; differential diagnoses of an infant with fever	11-month-old Olaf is not drinking well. He has been having fever since yesterday and has vomited once.	Undergraduate	-	CAMPUS- Classic	partly cleared	German	restricted	yes	Sören Huwendiek	soeren.huwendiek@med.uni-heidelberg.de
0.9 female	Medicine: Pediatrics - Nephrology / General Pediatrics	Cystinuria	11-month-old Franziska has abdominal pain. Her mother also noted blood in the diaper.	Undergraduate	-	CAMPUS- Classic	partly cleared	German	restricted	yes	Sören Huwendiek	soeren.huwendiek@med.uni-heidelberg.de
1.0 female	Medicine: Pediatrics - Hematology / Oncology	Beta-Thalassemia; differential diagnoses of anemia in childhood	12-month-old Selma is presented because of being so pallid.	Undergraduate	-	CAMPUS- Classic	partly cleared	German	restricted	yes	Sören Huwendiek	soeren.huwendiek@med.uni-heidelberg.de

1.2 female	Medicine: Pediatrics - Metabolic diseases	Glutaric aciduria	14-month-old Sylvia is presented by her parents because she was not responsive this morning when her mother tried to wake her.	Undergraduate	-	CAMPUS- Classic	partly cleared	German	restricted	yes	Sören Huwendiek	soeren.huwendiek@med.uni-heidelberg.de
1.2 male	Medicine: Pediatrics - Neurology	Fever seizure; differential diagnoses of seizures in childhood	20 minutes ago 15-month-old Paul started trembling with his whole body and was not responsive. It lasted for 2 minutes.	Undergraduate	-	CAMPUS- Classic	partly cleared	German	restricted	yes	Sören Huwendiek	soeren.huwendiek@med.uni-heidelberg.de
1.2 female	Medicine: Pediatrics - Gastroenterology / General Pediatrics	Coeliac disease; differential diagnoses of failure to thrive	15-month-old Anna-Lena is presented for a routine check in your private practice for the first time after moving to town.	Undergraduate	-	CAMPUS- Classic	partly cleared	German	restricted	yes	Sören Huwendiek	soeren.huwendiek@med.uni-heidelberg.de
1.5 female	Medicine: Pediatrics - Gastroenterology / General Pediatrics	Acute gastroenteritis	18-month-old Friederike has been having diarrhea for 2 days and vomited once.	Undergraduate	-	CAMPUS- Classic	partly cleared	German	restricted	yes	Sören Huwendiek	soeren.huwendiek@med.uni-heidelberg.de
2.1 male	Medicine: Pediatrics - Nephrology / General Pediatrics	Nephrotic syndrome; differential diagnoses of oedema and proteinuria in childhood	2-year-old Patrick is presented in the pediatric outpatient clinic because of bilaterally swollen eyelids.	Undergraduate	-	CAMPUS- Classic, - Card	partly cleared	German	restricted	yes	Sören Huwendiek	soeren.huwendiek@med.uni-heidelberg.de
2.1 female	Medicine: Pediatrics - Metabolic diseases	Diabetes mellitus type I	2-year-old Kerstin is presented in the pediatric outpatient clinic because she has been vomiting for 2 days and is uncommonly calm and tired.	Undergraduate	-	CAMPUS- Classic	partly cleared	German	restricted	yes	Sören Huwendiek	soeren.huwendiek@med.uni-heidelberg.de
2.2 female	Medicine: Pediatrics - Endocrinology	Hypophyseal failure to grow	Mareike is presented by her mother, who feels that her daughter is too small and ceased to grow.	Undergraduate	-	CAMPUS- Classic	partly cleared	German	restricted	yes	Sören Huwendiek	soeren.huwendiek@med.uni-heidelberg.de
2.2 female	Medicine: Pediatrics - Hematology / Oncology	Acute lymphocytic leukemia	2-year-old Manuela has been having fever and a sore throat for a week and is strikingly pale. Her parents present her in the pediatric outpatient clinic.	Undergraduate	-	CAMPUS- Classic	partly cleared	German	restricted	yes	Sören Huwendiek	soeren.huwendiek@med.uni-heidelberg.de
2.8 male	Medicine: Pediatrics - Hematology / Oncology	Idiopathic thrombocytopenic purpura; differential diagnoses of thrombocytopenia, leukemia	Jochen is presented because he has strikingly many bruises.	Undergraduate	-	CAMPUS- Classic	partly cleared	German	restricted	yes	Sören Huwendiek	soeren.huwendiek@med.uni-heidelberg.de
3.0 male	Medicine: Pediatrics - Neurology	Duchenne muscular dystrophy	3 year old Paul is presented by his mother, who noticed that he stumbles quite often, is clumsy and also refuses to climb stairs.	Undergraduate	-	CAMPUS- Classic	partly cleared	German	restricted	yes	Sören Huwendiek	soeren.huwendiek@med.uni-heidelberg.de

3.0 female	Medicine: Pediatrics - Gastroenterology / General Pediatrics	Foreign body ingestion	3-year-old Claudia has been eating only liquids and refusing solid foods for two weeks now. She lost 2 kg.	Undergraduate	-	CAMPUS- Classic	partly cleared	German	restricted	yes	Sören Huwendiek	soeren.huwendiek@med.uni-heidelberg.de
3.0 female	Medicine: Pediatrics - Pneumology	Complicated pulmonary tuberculosis; differential diagnoses of chronic cough	3-year-old Öga has a chronic cough and is presented in the pediatric pulmonary outpatient clinic.	Undergraduate	-	CAMPUS- Classic	partly cleared	German	restricted	yes	Sören Huwendiek	soeren.huwendiek@med.uni-heidelberg.de
3.0 female	Medicine: Pediatrics - Pneumology	Pneumonia with atypical presentation (fever and stomach pain)	3-year-old Katja has abdominal pain and fever and is presented by her parents in the emergency pediatric outpatient clinic at night.	Undergraduate	-	CAMPUS- Classic	partly cleared	German	restricted	yes	Sören Huwendiek	soeren.huwendiek@med.uni-heidelberg.de
3.4 male	Medicine: Pediatrics - Intensive care medicine	Foreign body aspiration, differential diagnoses of cough and abnormal breathing sounds	3-year-old Daniel has been having recurrent respiratory tract infections and coughs for months, and currently sounds strange when breathing.	Undergraduate	-	CAMPUS- Classic	partly cleared	German	restricted	yes	Sören Huwendiek	soeren.huwendiek@med.uni-heidelberg.de
4.0 male	Medicine: Pediatrics - General Pediatrics	Coxitis fugax, differential diagnoses of a limping child	4-year-old Klaus is brought to the clinic by his mother, because of pain in his right leg and limping since three days.	Undergraduate	http://galaxy.mi.hs-heilbronn.de:3333/myzms/content/e54/e351/e372/index_ger.html	CAMPUS- Classic/ - Card	partly cleared	German	open	yes	Sören Huwendiek	soeren.huwendiek@med.uni-heidelberg.de
6.0 male	Medicine: Pediatrics - Neurology	Benign rolandic epilepsy	6-year-old Joachim is brought by his parents to the emergency pediatric outpatient clinic because of unclear impaired consciousness this morning.	Undergraduate	-	CAMPUS- Classic	partly cleared	German	restricted	yes	Sören Huwendiek	soeren.huwendiek@med.uni-heidelberg.de
6.1 male	Medicine: Pediatrics - Nephrology / General Pediatrics	Poststreptococcal glomerulonephritis; differential diagnoses: hematuria, nephritic syndrome, acute renal failure	A 6-year-old boy is brought to the pediatric outpatient clinic because he somehow feels bad. He has hardly eaten and vomited twice, further he has slightly swollen eyes.	Undergraduate	-	CAMPUS- Classic, - Card	partly cleared	German	restricted	yes	Sören Huwendiek	soeren.huwendiek@med.uni-heidelberg.de
6.5 female	Medicine: Pediatrics - Metabolic diseases	Ornithine transcarbamylase (OTC) deficiency	At nighttime an ambulance brings a 6-year-old girl in a comatose state to the pediatric clinic.	Undergraduate	-	CAMPUS- Classic	partly cleared	German	restricted	yes	Sören Huwendiek	soeren.huwendiek@med.uni-heidelberg.de
7.0 male	Medicine: Pediatrics - Infectiology	Varicella infection (chickenpox)	A GP transfers a 7-year-old boy with exanthema for 4 days to the pediatric clinic. His state worsened during the last day and he is hardly able to eat.	Undergraduate	-	CAMPUS- Classic	partly cleared	German	restricted	yes	Sören Huwendiek	soeren.huwendiek@med.uni-heidelberg.de

12.0 female	Medicine: Pediatrics - Endocrinology	Graves' Disease	12-year-old Stefanie comes with her mother to the pediatric outpatient clinic because since weeks she is increasingly agitated and has problems at school.	Undergraduate	-	CAMPUS-Classic	partly cleared	German	restricted	yes	Sören Huwendiek	soeren.huwendiek@med.uni-heidelberg.de
14.0 female	Medicine: Pediatrics - Nephrology / General Pediatrics	Glomerulonephritis with lupus erythematosus	A 14-year-old girl comes with her mother to the pediatric outpatient clinic because collapsed in school today.	Undergraduate	-	CAMPUS-Classic	partly cleared	German	restricted	yes	Sören Huwendiek	soeren.huwendiek@med.uni-heidelberg.de
15.0 female	Medicine: Pediatrics - Cardiology	Aortic coarctation; differential diagnosis of arterial hypertension	15-year-old Yasmin discovered high blood pressure during a routine check at a pharmacy and comes with her mother to the pediatric outpatient clinic.	Undergraduate	-	CAMPUS-Classic	partly cleared	German	restricted	yes	Sören Huwendiek	soeren.huwendiek@med.uni-heidelberg.de

VP Title	VP Age	VP Sex	Discipline e.g medicine, nursing	Clinical topics	Brief description	Educational level	IPR	URL if available	VP system	Language	Access rights	Has been used by students?	Contact name	Contact email
VP.1.WebSP. Cluj	20	Female	Medicine / Endocrinology	Neck mass	Female patient with a thyroid gland nodule	Undergraduate	Cleared	http://vpmed.umfcluj.ro/webSP , user=password= evip	WebSP	Romanian and English	Open case	Yes	Rares Bosu	bosu_rares@yahoo.com
VP.2.WebSP. Cluj	61	Female	Medicine / Endocrinology	Abnormal serum calcium	Female patient with hypercalcemia and parathyroid tumor	Undergraduate	Cleared	http://vpmed.umfcluj.ro/webSP , user=password= evip	WebSP	Romanian and English	Open case	Yes	Rares Bosu	bosu_rares@yahoo.com
VP.3.WebSP. Cluj	75	Female	Medicine / Gastroenterology	Abdominal pain / Vomiting	Female aptient with peptic ulcer disease and gastric outlet obstruction	Undergraduate	Cleared	http://vpmed.umfcluj.ro/webSP , user=password= evip	WebSP	Romanian and English	Open case	Yes	Alina Barz	alina_792003@yahoo.com
VP.4.WebSP. Cluj	71	Male	Medicine / Gastroenterology	Abdominal epigastric pain	Male patient with malignant neoplasm of the stomach	Undergraduate	Cleared	http://vpmed.umfcluj.ro/webSP , user=password= evip	WebSP	Romanian and English	Open case	Yes	Cosmin Valcu	obamg3@yahoo.com
VP.5.WebSP. Cluj	23	Female	Medicine / Oncology	Breast tumor	Female patient with a recurrent breast tumor after previous surgery	Postgraduate	Cleared	Available soon	WebSP	Romanian	Open case	No	George Dindelegan	gindelegan@yahoo.com
VP.6.WebSP. Cluj	42	Male	Medicine / Dermatology	Skin tumor	Male patient with malignant melanocitic tumor of the anterior abdomen	Undergraduate	Cleared	Available soon	WebSP	English	Open case	No	George Dindelegan	gindelegan@yahoo.com
VP.7.WebSP. Cluj	76	Male	Medicine / Dermatology	Skin blisters	Male patient with generalized skin blisters and rash	Undergraduate	Cleared	Available soon	WebSP	Romanian	Open case	Yes	Alexandru Tataru	alexandru.tataru@hotmail.ro
VP.8.WebSP. Cluj	48	Female	Medicine / Dermatology	Skin erythema and dermatitis	Female patient with face, trunk and hands erythematous-squamous plaques	Undergraduate	Cleared	Available soon	WebSP	Romanian	Open case	No	Alexandru Tataru	alexandru.tataru@hotmail.ro
VP.9.WebSP. Cluj	71	Male	Medicine / Urology	Voiding disturbances	Polakiuria and dysuria in a male patient with prostate hypertrophy	Undergraduate	Cleared	Available soon	WebSP	English	Open case	No	Gabriel Kacso	gabi.kacso@gmail.com
VP.10.WebSP. Cluj	52	Female	Medicine / Gynecology	Vaginal bleeding	Vaginal bleeding in a perimenopausal woman with cervical tumor	Undergraduate	Cleared	Available soon	WebSP	English	Open case	No	Gabriel Kacso	gabi.kacso@gmail.com
VP.11.WebSP. 7 w Cluj		Male	Medicine / Pediatrics	Abnormal serum sodium	Infant deceased with hypernatremic dehydration	Postgraduate	Cleared	Available soon	WebSP	Romanian	Open case	Yes	Mihai Militaru	militarumihai@yahoo.com
VP.12.WebSP. Cluj	35	Male	Medicine / Ophtalmology	Visual loss	Male patient with ocular pain and visual loss, two years after a minor ocular trauma	Undergraduate	Cleared	Available soon	WebSP	Romanian	Open case	No	Simona Talu	simonatalu@yahoo.com
VP.13.WebSP. Cluj	45	Male	Medicine / Ophtalmology	Blurred vision	Male patient with a two months history of unilateral blurred vision, with no other complaints	Postgraduate	Cleared	Available soon	WebSP	English	Open case	Yes	Simona Talu	simonatalu@yahoo.com
VP.14.WebSP. Cluj	33	Female	Medicine / Ophtalmology	Diplopia	Female with spontaneous binocular diplopia and abduction of the right eye, no history of trauma	Postgraduate	Cleared	Available soon	WebSP	Romanian and English	Open case	No	Bianca Szabo	biszabo4862@yahoo.com
VP.15.WebSP. Cluj	68	Female	Medicine / Ophtalmology	Red eye	Female patient with bilateral red eye, decreased vision, bruit and bulging eyeballs	Postgraduate	Cleared	Available soon	WebSP	Romanian and English	Open case	No	Bianca Szabo	biszabo4862@yahoo.com
VP.16.WebSP. Cluj	39	Female	Medicine / Ophtalmology	Visual disturbance	Female patient with unilateral visual disturbance	Postgraduate	Cleared	Available soon	WebSP	Romanian	Open case	Yes	Laura Stanila	lau_ovi@yahoo.com

VP.17.WebSP. Cluj	48 Male	Medicine / Ophtalmology	Visual disturbance / loss	Male patinent with bilateral visual disturbance / loss	Undergraduate	Cleared	Available soon	WebSP	Romanian	Open case	No	Laura Stanila	lau_ovi@yahoo.com
VP.18.WebSP. Cluj	67 Male	Medicine / Gastroenterology	Generalized pruritus	Male patient with recent generalized proritul, loss of appetite and jaundice	Postgraduate	Cleared	Available soon	WebSP	Romanian	Open case	Yes	Florin Casoinic	fcasoinic@yahoo.com
VP.19.WebSP. Cluj	77 Female	Medicine / Cardiology	Syncope	Female patient with 10 episodes of loss of consciousness after physical exercise	Undergraduate	Cleared	Available soon	WebSP	Romanian	Open case	No	Florin Casoinic	fcasoinic@yahoo.com
VP.20.WebSP. Cluj	35 Male	Medicine / Psychiatry	Psychotic patient / Disordered thought	Male patient with imperative auditive hallucinations, anxiety and insomnia	Undergraduate	Cleared	Available soon	WebSP	Romanian	Open case	No	Liana Don	lianadon@yahoo.com
VP.21.WebSP. Cluj	39 Male	Medicine / Psychotherapy	Panic and anxiety	Paroxistic anxiety, palpitations and sensation of imminent death	Undergraduate	Cleared	Available soon	WebSP	Romanian	Open case	No	Liana Don	lianadon@yahoo.com
VP.22.WebSP. Cluj	25 Male	Medicine / Endocrinology	Hyperglycemia / Diabetes mellitus	Young male with no relevant familial history and recent polydispsia, astenia and weight loss	Undergraduate	Cleared	Available soon	WebSP	Romanian and English	Open case	Yes	Cornelia Bala	cbala@umfcluj.ro
VP.23.WebSP. Cluj	34 Male	Medicine / Endocrinology	Abnormal serum lipids	Young male with no complains and a familial history of diabetes mellitus, coming for the periodic health examination	Undergraduate	Cleared	Available soon	WebSP	Romanian and English	Open case	Yes	Cornelia Bala	cbala@umfcluj.ro
VP.24.WebSP. Cluj	55 Female	Medicine / Endocrinology	Weight gain / Obesity	Postmenopausal female patient, recently retired, with a weight gain of 25 pounds during the last 12 months	Undergraduate	Cleared	Available soon	WebSP	Romanian and English	Open case	Yes	Cornelia Bala	cbala@umfcluj.ro
VP.25.WebSP. Cluj	64 Female	Medicine / Gynecology	Prolapse / Pelvic relaxation	Female patient with urinary incontinence, polakiuria and constipation	Undergraduate	Cleared	Available soon	WebSP	Romanian	Open case	No	Timis Gavrilă	gabi_timis@yahoo.com
VP.26.WebSP. Cluj	43 Female	Medicine / Oncology	Breast tumor	Female patient with a breast mass	Undergraduate	Cleared	Available soon	WebSP	Romanian	Open case	No	Timis Gavrilă	gabi_timis@yahoo.com
VP.27.WebSP. Cluj	45 Female	Medicine / Radiology	Abnormal mammogram	Female pateint with a 4 mm stelate breast lesion on mammogram, unchanged for 3 years	Postgraduate	Cleared	Available soon	WebSP	English	Open case	No	Anca Ciurea	ancaciurea@hotmail.com
VP.28.WebSP. Cluj	36 Female	Medicine / Radiology	Lymphadenopathy	Female patinet with painfull lymph node in the supraclavicular fossa	Postgraduate	Cleared	Available soon	WebSP	English	Open case	No	Anca Ciurea	ancaciurea@hotmail.com
VP.29.WebSP. Cluj	34 Female	Medicine / Rheumatology	Chronic arthralgia / Hypertension	Patient with Raynaud phenomenon, arthralgia, loss of skin wrinkles, dyspnea , dysphagia and blurred vision	Undergraduate	Cleared	Available soon	WebSP	Romanian	Open case	Yes	Simona Rednic	srednic@umfcluj.ro
VP.30.WebSP. Cluj	60 Female	Medicine / Rheumatology	Chronic arthralgia	Female patient with arthralgia in small-finger joints and both wrists, prolonged morning stiffness	Undergraduate	Cleared	Available soon	WebSP	English	Open case	No	Simona Rednic	srednic@umfcluj.ro

VP.31.WebSP. Cluj	48 Male	Medicine / Gastroenterology	Abdominal pain / Bone pain	Male patient with epigastric, vertebral and clavicular pain, pancreatic and clavicular tumor and duodenal obstruction	Postgraduate	Cleared	Available soon	WebSP	Romanian	Open case	Yes	Dorel Sampalean dorelsampelean@hotmail.com
VP.32.WebSP. Cluj	67 Male	Medicine / Gastroenterology	Abdominal pain / Vomiting	Male patient with gastric adenocarcinoma who refuses surgical treatment	Undergraduate	Cleared	Available soon	WebSP	Romanian	Open case	Yes	Dorel Sampalean dorelsampelean@hotmail.com
VP.33.WebSP. Cluj	21 Male	Medicine / Psychiatry	Panic and anxiety	Young patient with paroxysmic anxiety, phobia of open spaces and insomnia	Undergraduate	Cleared	Available soon	WebSP	Romanian	Open case	No	Iasmina Dragomir yasmina63us@yahoo.com
VP.34.WebSP. Cluj	37 Male	Medicine / Psychiatry	Psychotic disorders	Male patient with delusions, auditory and haptic hallucinations and disturbed behavior	Undergraduate	Cleared	Available soon	WebSP	English	Open case	No	Iasmina Dragomir yasmina63us@yahoo.com
VP.35.WebSP. Cluj	68 Female	Medicine / Gastroenterology	Jaundice	Female patient with jaundice, severe back pain and weight loss	Undergraduate	Cleared	Available soon	WebSP	English	Open case	No	Doru Muntean dr_munteanu_doru@yahoo.com
VP.36.WebSP. Cluj	69 Male	Medicine / Gastroenterology	Hematemesis	Male patient on anticoagulant treatment with abdominal pain, pallor and hematemesis after abdominal trauma	Postgraduate	Cleared	Available soon	WebSP	English	Open case	Yes	Doru Muntean dr_munteanu_doru@yahoo.com

Ref ID	Institution	VP Title	VP Age	VP Sex	Discipline e.g medicine, nursing	Clinical topics
evip_pl_1	Jagiellonian University, Medical College	78-letnia kobieta z masywnymi krwinkami (Marta Terlecka)	78	Female	Medicine: Haematology	Coagulopathy
evip_pl_2	Jagiellonian University, Medical College	20-letnia pacjentka ze spuchniętą twarzą (Janina Kowalska)	20	Female	Medicine: Allergology	Hereditary Angioedema
evip_pl_4	Jagiellonian University, Medical College	19-letnia uczennica z bólem gardła (Ch. Schulte)	19	Female	Medicine: Infectiology	Infectious mononucleosis
evip_pl_7	Jagiellonian University, Medical College	57-letnia agentka ubezpieczeniowa z suchości oczu i jamy ustnej (Zofia Gochecka)	57	Female	Medicine: Rheumatology	Sjögren's syndrome

Brief description	Educational level	URL if available	VP system	IPR	Language	Access rights	Has been used by students?	Contact name	Contact email
A 78-year old female with large haematoma	Undergraduate	-	CASUS		Polish		Yes	A.Kononowicz; A.Stachoń	a.kononowicz@cyfronet.pl ; orchis@o2.pl
A 20-year old female with swollen face	Undergraduate	-	CASUS		Polish		Yes	A.Kononowicz; A.Stachoń	a.kononowicz@cyfronet.pl ; orchis@o2.pl
A 19-year old with sore throat	Undergraduate	-	CASUS		Polish		No	A.Kononowicz; A.Stachoń	a.kononowicz@cyfronet.pl ; orchis@o2.pl
A 57-year old insurance agent with xerostomia and xerophthalmia	Undergraduate	-	CASUS		Polish		No	A.Kononowicz; A.Stachoń	a.kononowicz@cyfronet.pl ; orchis@o2.pl

Inventory of existing VP cases complete with any IPR issues and report on which VP cases that will be repurposed, medical/healthcare speciality targeted and responsible partner

eViP – Electronic Virtual Patient
www.virtualpatients.eu

Annex B – Statistical findings (raw data)

VP	Institution	VP Age	VP Sex	Discipline	Educational level	VP system	IPR	Language	Access rights	Used by students?
1		1 40	0		1	1	1	2	1 0	1
2		1 65	1		1	1	1	2	1 0	1
3		1 14	0		1	1	1	2	1 0	1
4		1 64	0		1	1	1	1	1 0	1
5		1 26	1		1	1	1	1	1 0	1
6		1 27	0		1	1	1	1	1 0	1
7		1 34	0		1	1	1	1	1 0	1
8		1 26	1		1	1	1	1	1 0	1
9		1 60	0		1	1	1	1	1 0	1
10		1 29	0		1	1	1	1	1 0	1
11		1 18	0		1	1	1	1	1 0	1
12		1 29	1		3	1	1	1	1 0	1
13		1 50	0		1	1	1	1	1 0	1
14		1 25	1		6	1	1	1	1 0	1
15		1 46	0		1	1	1	1	1 0	1
16		1 50	0		1	1	1	1	1 0	1
17		1 45	0		1	1	1	1	1 0	1
18		1 0.75	1		1	1	1	1	1 0	1
19		1 0.5	1		1	1	1	1	1 0	1
20		1 0.5	0		1	1	1	1	1 0	1
21		1 34	1		1	1	1	1	1 0	1
22		1 25	0		1	1	1	1	1 0	1
23		1 80	0		1	1	1	1	1 0	1
24		1 0.58	0		1	1	1	1	1 0	1
25		1 5	1		1	1	1	1	1 0	1
26		1 0.1	1		1	1	1	1	1 0	1
27		1 0	0		1	1	1	1	1 0	1
28		1 86	1		2	1	1	0	1 0	0
29		1 40	1		1	1	1	0	1 0	0
30		1 37	1		2	1	1	0	1 0	0
31		1 36	0		2	1	1	0	1 0	0
32		1 60	0		2	1	1	0	1 0	0
33		1 32	0		2	1	1	0	1 0	0
34		1 30	0		1	1	1	0	1 0	0
35		1 45	1		2	1	1	0	1 0	0
36		1 45	0		5	1	1	0	1 0	0
37		1 80	0		1	1	1	0	1 0	0
38		1 46	0		1	1	1	0	1 0	0
39		1 34	0		1	1	1	0	1 0	0
40		1 40	1		1	1	1	0	1 0	0
41		1 48	0		1	1	1	0	1 0	0
42		1 35	1		2	1	1	0	1 0	0
43		1			1	1	1	0	1 0	0
44		2 44		1	5	1	2	2	1 0	1
45		2 51		0	4	1	2	2	1 0	1
46		2 62		1	4	1	2	2	1 0	1
47		2 50		0	4	1	2	2	1 0	1
48		2 76		0	4	1	2	2	1 0	1
49		2 66		0	4	1	2	2	1 0	1
50		2 44		0	4	1	2	2	1 0	1
51		2 74		1	4	1	2	2	1 0	1
52		2 57		1	4	1	2	2	1 0	1
53		2 28		0	4	1	2	2	1 0	1
54		2 49		1	4	1	2	2	1 0	1
55		2 43		1	4	1	2	2	1 0	1
56		2 41		0	4	1	2	2	1 0	1
57		2 72		0	4	1	2	2	1 0	1
58		2 60		0	4	1	2	2	1 0	1
59		2 57		1	4	1	2	2	1 0	1
60		2 11		0	1	1	2	2	1 0	1
61		2 36		1	1	1	2	2	1 0	1
62		2 29		1	1	1	2	2	1 0	1
63		2 34		1	1	1	2	2	1 0	1
64		2 0.5		1	1	1	2	2	1 0	1
65		2 2		0	1	1	2	2	1 0	1
66		2 15		1	1	1	2	2	1 0	1
67		2 75		0	1	1	2	2	1 0	1
68		2 65		1	1	1	2	2	1 0	1
69		2 82		1	1	1	2	2	1 0	1
70		2 38		1	1	1	2	2	1 0	1
71		2 46		1	1	1	2	2	1 0	1
72		2 67		0	1	1	2	2	1 0	1
73		2 83		0	1	1	2	2	1 0	1
74		2 40		0	1	1	2	2	1 0	1
75		2 46		1	1	1	2	2	1 0	1
76		2 59		0	1	1	2	2	1 0	1
77		2 45		1	1	1	2	2	1 0	1
78		2 12		0	1	1	2	2	1 0	1
79		2 44		0	1	1	2	1	1 0	1
80		2 36		1	1	1	2	1	1 0	1
81		2 20		0	1	1	2	1	1 0	1
82		2 59		1	1	1	2	1	1 0	1

83	2 28	0	1	1	2	1	1 0	1
84	2 44	1	4	1	2	2	4 0	1
85	2 51	0	4	1	2	2	4 0	1
86	2 62	1	4	1	2	2	4 0	1
87	2 50	0	4	1	2	2	4 0	1
88	2 76	0	4	1	2	2	4 0	1
89	2 66	0	4	1	2	2	4 0	1
90	2 44	0	4	1	2	2	4 0	1
91	2 74	1	4	1	2	2	4 0	1
92	2 57	1	4	1	2	2	4 0	1
93	2 28	0	4	1	2	2	4 0	1
94	2 49	1	4	1	2	2	4 0	1
95	2 43	1	4	1	2	2	4 0	1
96	2 41	0	4	1	2	2	4 0	1
97	2 72	0	4	1	2	2	4 0	1
98	2 60	0	4	1	2	2	4 0	1
99	2 57	1	4	1	2	2	4 0	1
100	2 73	1	1	1	2	2	4 0	1
101	2 25	1	1	1	2	2	4 0	1
102	2 36	0	1	1	2	2	4 0	1
103	2 56	1	1	1	2	2	4 0	1
104	2 2.5	0	1	1	2	2	4 0	1
105	2 3	0	1	1	2	2	4 0	1
106	2 43	0	1	1	2	1	4 0	1
107	2 32	0	1	1	2	1	4 0	1
108	2 52	1	1	1	2	1	4 0	1
109	2 35	1	1	1	2	1	4 0	1
110	2 14	0	1	1	2	1	4 0	1
111	2 62	0	1	1	2	1	4 0	1
112	2 13	1	1	1	2	1	4 0	1
113	2 22	0	1	1	2	2	4 0	1
114	2 39	0	1	1	2	2	4 0	1
115	2 59	1	2	1	2	2	4 0	1
116	2 86	1	2	1	2	2	4 0	1
117	2 32	0	2	1	2	2	4 0	1
118	2 32	0	2	1	2	2	4 0	1
119	2 71	1	2	1	2	2	4 0	1
120	2 71	1	2	1	2	2	4 0	1
121	2 25	1	2	1	2	2	4 0	1
122	2 40	1	1	1	2	2	4 0	1
123	2 30	1	1	1	2	2	4 0	1
124	2 50	1	1	1	2	2	4 0	1
125	2 41	0	1	1	2	2	4 0	1
126	2 55	1	1	1	2	2	4 0	1
127	2 45	1	1	1	2	2	4 0	1
128	2 71	0	1	1	2	2	4 0	1
129	3 40	0	1	1	4	2	1 0	1
130	3 47	1	1	1	4	2	1 0	1
131	3 43	1	1	1	4	2	1 0	1
132	3 48	0	1	1	4	2	1 0	1
133	3 57	1	1	1	4	2	2 0	1
134	3 58	1	1	1	4	2	2 0	1
135	3 78	1	1	1	4	2	2 0	1
136	3 72	1	1	1	4	2	2 0	1
137	3 69	1	1	1	4	2	2 0	1
138	3 35	1	1	1	4	2	2 0	1
139	3 28	0	1	1	4	2	2 0	1
140	3 54	0	1	1	4	2	2 0	1
141	3 19	1	1	1	4	2	2 0	1
142	3 35	0	1	1	4	2	2 0	1
143	3 32	0	1	1	4	2	2 0	1
144	3 56	1	1	1	4	2	2 0	1
145	3 39	1	1	1	4	2	2 0	1
146	3 40	0	1	1	4	2	2 0	1
147	3 54	0	1	1	4	2	2 0	1
148	3 61	0	1	1	4	2	2 0	1
149	3 66	1	1	1	4	2	2 0	1
150	3 59	1	1	1	4	2	2 0	1
151	3 45	1	1	1	4	2	2 0	1
152	3 40	0	1	1	4	2	2 0	1
153	3 45	1	1	1	4	2	2 0	1
154	3 35	1	1	1	4	2	2 0	1
155	3 75	1	1	1	4	2	2 0	1
156	3 24	1	1	1	4	2	2 0	1
157	3 79	0	1	1	4	2	2 0	1
158	3 69	0	1	1	4	2	2 0	1
159	3 33	1	1	1	4	2	2 0	1
160	3 77	0	1	1	4	2	2 0	1
161	3 38	0	1	1	4	2	2 0	1
162	3 37	0	1	1	4	2	2 0	1
163	3		1	3	4	2	2 0	1
164	3		1	3	4	2	2 0	1
165	3		1	3	4	2	2 0	1


166	3		1	3	4	2	2 0	1
167	3		1	3	4	2	2 0	1
168	3		1	3	4	2	2 0	1
169	3		1	3	4	2	2 0	1
170	3		1	3	4	2	2 0	1
171	3 73	0	1	1	4	2	2 0	1
172	3 37	0	1	1	4	2	2 0	1
173	3 61	1	1	1	4	2	2 0	1
174	3 52	0	1	1	4	2	2 0	1
175	3 24	1	1	1	4	2	2 0	1
176	3 35	0	1	1	4	0	2 0	1
177	3	1	1	1	4	2	2 0	1
178	3 21	0	1	1	4	2	2 0	1
179	3 30	1	1	1	4	2	2 0	1
180	3 63	0	1	1	4	2	2 0	1
181	3 23	0	1	1	4	2	1 0	0
182	3 62	1	1	1	4	2	2 0	1
183	3		1	1	4	2	2 0	0
184	3 30	0	1	1	4	2	2 0	1
185	3 35	1	1	1	4	2	2 0	1
186	3 21	0	1	1	4	2	2 0	1
187	3 76	1	1	1	4	2	2 0	1
188	3 33	1	1	1	4	2	2 0	1
189	3 43	1	1	1	4	2	2 0	1
190	3 69	1	1	1	4	2	2 0	1
191	3 16	1	1	1	4	2	2 0	1
192	3 70	1	1	1	4	2	2 0	1
193	3 45	1	1	1	4	2	2 0	1
194	3 52		1	1	4	2	2 0	1
195	3		1	3	4	2	2 0	1
196	3 79	1	1	1	4	2	2 0	1
197	3		1	1	4	0	2 0	0
198	3 0.5	0	1	1	4	0	2 0	1
199	3 2	0	1	1	4	0	2 0	1
200	3 <1	1	1	1	4	0	2 0	1
201	3 3	1	1	1	4	0	2 0	1
202	3	0	1	1	4	0	2 0	1
203	3 78	0	1	1	4	0	2 0	1
204	3 66	1	1	1	4	0	2 0	1
205	3 13	1	1	1	4	2	2 0	1
206	3 12	1	1	1	4	2	2 0	1
207	3 17	0	1	1	4	2	1 0	1
208	3 19	1	1	1	4	2	1 0	1
209	3	0	1	1	4	2	1 0	1
210	3 65	0	1	1	4	0	2 0	1
211	3 30	1	1	1	4	0	2 0	1
212	3 71	1	1	1	4	2	2 0	1
213	4 45	0	1	1	5	0	1 0	1
214	4 70	0	1	1	5	0	1 0	1
215	4 0	1	1	1	5	0	1 0	1
216	4 80	1	1	1	5	0	1 0	1
217	4 10	1	1	1	5	0	1 0	1
218	4 77	1	1	1	5	0	1 0	1
219	4 42	1	1	1	5	0	1 0	1
220	4 82	1	1	1	5	0	1 0	1
221	4 33	0	1	1	5	0	1 0	1
222	4 47	1	1	1	5	0	1 0	1
223	4 28	1	1	1	5	0	1 0	1
224	4 16	1	1	1	5	0	1 0	1
225	4 71	0	1	1	5	0	1 0	1
226	4 68	0	1	1	5	0	1 0	1
227	4 81	0	1	1	5	0	1 0	1
228	4 28	0	1	1	5	0	1 0	1
229	4 23	0	1	1	5	0	1 0	1
230	4 31	1	1	1	5	0	1 0	1
231	4 22	1	1	1	5	0	1 0	1
232	4 93	1	1	1	5	0	1 0	1
233	4 48	1	1	1	5	0	1 0	1
234	4 15	1	1	1	5	0	1 0	1
235	4 5	1	1	1	5	0	1 0	1
236	4 39	1	1	1	5	0	1 0	1
237	4 55	1	1	1	5	0	1 0	1
238	4 58	0	1	1	5	0	1 0	1
239	4 18	1	1	1	5	0	1 0	1
240	4 19	0	1	1	5	0	1 0	1
241	4 60	1	1	1	5	0	1 0	1
242	4 15	1	1	1	5	0	1 0	1
243	5 65	0	1	1	3	1	1 0	1
244	5 75	0	1	1	3	1	1 0	1
245	5 70	0	1	1	3	1	1 0	1
246	5 24	0	1	1	3	1	1 0	1
247	5 61	1	1	1	3	1	1 0	1
248	5 1	0	1	1	3	1	3 0	1

249	5 10	0	1	1	3	1	3 0	1
250	5 6	0	1	1	3	1	3 0	1
251	5 10	1	1	1	3	1	3 0	1
252	5 3	0	1	1	3	1	3 0	1
253	6 0.0	0	1	1	3	1	2 0	1
254	6 0.0	0	1	1	3	1	2 0	1
255	6 0.0	1	1	1	3	1	2 0	1
256	6 0.0	0	1	1	3	1	2 0	1
257	6 0.0	0	1	1	3	1	2 0	1
258	6 0.0	0	1	1	3	1	2 0	1
259	6 0.0	0	1	1	3	1	2 0	1
260	6 0.1	0	1	1	3	1	2 0	1
261	6 0.1	0	1	1	3	1	2 0	1
262	6 0.1	0	1	1	3	1	2 1	1
263	6 0.2	0	1	1	3	1	2 0	1
264	6 0.4	1	1	1	3	1	2 1	1
265	6 0.5	0	1	1	3	1	2 0	1
266	6 0.7	1	1	1	3	1	2 0	1
267	6 0.7	0	1	1	3	1	2 0	1
268	6 0.9	0	1	1	3	1	2 0	1
269	6 0.9	1	1	1	3	1	2 0	1
270	6 1.0	1	1	1	3	1	2 0	1
271	6 1.2	1	1	1	3	1	2 0	1
272	6 1.2	0	1	1	3	1	2 0	1
273	6 1.2	1	1	1	3	1	2 0	1
274	6 1.5	1	1	1	3	1	2 0	1
275	6 2.1	0	1	1	3	1	2 0	1
276	6 2.1	1	1	1	3	1	2 0	1
277	6 2.2	1	1	1	3	1	2 0	1
278	6 2.2	1	1	1	3	1	2 0	1
279	6 2.8	0	1	1	3	1	2 0	1
280	6 3.0	0	1	1	3	1	2 0	1
281	6 3.0	1	1	1	3	1	2 0	1
282	6 3.0	1	1	1	3	1	2 0	1
283	6 3.0	1	1	1	3	1	2 0	1
284	6 3.4	0	1	1	3	1	2 0	1
285	6 4.0	0	1	1	3	1	2 1	1
286	6 6.0	0	1	1	3	1	2 0	1
287	6 6.1	0	1	1	3	1	2 0	1
288	6 6.5	1	1	1	3	1	2 0	1
289	6 7.0	0	1	1	3	1	2 0	1
290	6 12.0	1	1	1	3	1	2 0	1
291	6 14.0	1	1	1	3	1	2 0	1
292	6 15.0	1	1	1	3	1	2 0	1
293	7 20	1	1	1	2	2	5 0	1
294	7 61	1	1	1	2	2	5 0	1
295	7 75	1	1	1	2	2	5 0	1
296	7 71	0	1	1	2	2	5 0	1
297	7 23	1	1	2	2	2	5 0	0
298	7 42	0	1	1	2	2	1 0	0
299	7 76	0	1	1	2	2	5 0	1
300	7 48	1	1	1	2	2	5 0	0
301	7 71	0	1	1	2	2	1 0	0
302	7 52	1	1	1	2	2	1 0	0
303	7 0.15	0	1	2	2	2	5 0	1
304	7 35	0	1	1	2	2	5 0	0
305	7 45	0	1	2	2	2	1 0	1
306	7 33	1	1	2	2	2	5 0	0
307	7 68	1	1	2	2	2	5 0	0
308	7 39	1	1	2	2	2	5 0	1
309	7 48	0	1	1	2	2	5 0	0
310	7 67	0	1	2	2	2	5 0	1
311	7 77	1	1	1	2	2	5 0	0
312	7 35	0	1	1	2	2	5 0	0
313	7 39	0	1	1	2	2	5 0	0
314	7 25	0	1	1	2	2	5 0	1
315	7 34	0	1	1	2	2	5 0	1
316	7 55	1	1	1	2	2	5 0	1
317	7 64	1	1	1	2	2	5 0	0
318	7 43	1	1	1	2	2	5 0	0
319	7 45	1	1	2	2	2	1 0	0
320	7 36	1	1	2	2	2	1 0	0
321	7 34	1	1	1	2	2	5 0	1
322	7 60	1	1	1	2	2	1 0	0
323	7 48	0	1	2	2	2	5 0	1
324	7 67	0	1	1	2	2	5 0	1
325	7 21	0	1	1	2	2	5 0	0
326	7 37	0	1	1	2	2	1 0	0
327	7 68	1	1	1	2	2	1 0	0
328	7 69	0	1	2	2	2	1 0	1
329	8 78	1	1	1	4	0	6 0	1
330	8 20	1	1	1	4	0	6 0	1
331	8 19	1	1	1	4	0	6 0	0

332 8 57 1 1 1 4 0 6 0 0

Annex C – Project plan for deliverable 3.1

ID		Task Name	Duration	Start	Finish	Predecessors						04 Feb '08	
							W	T	F	S	S	M	T
1	✓	Deliverable 3.1 Inventory of Existing VP cases and report	21 days	Fri 01/02/08	Fri 29/02/08								
2	✓	Modify existing table of fields in Excel to match the DOW	1 day	Fri 01/02/08	Fri 01/02/08								
3	✓	Populate existing table for each partners' VPs	9 days	Mon 04/02/08	Thu 14/02/08	2							
4	✓	Collate all partners' tables into an eViP inventory list	1 day	Fri 15/02/08	Fri 15/02/08	3							
5	✓	Highlight key trends from the inventory list	1 day	Mon 18/02/08	Mon 18/02/08	4							
6	✓	Create one-page summary of the inventory list	2 days	Tue 19/02/08	Wed 20/02/08	5							
7	✓	Review by all partner leads	2 days	Thu 21/02/08	Fri 22/02/08	6							
8	✓	Changes based on review	1 day	Mon 25/02/08	Mon 25/02/08	7							
9	✓	Final sign-off by all partners	2 days	Tue 26/02/08	Wed 27/02/08	8							
10	✓	Submit deliverable	2 days	Thu 28/02/08	Fri 29/02/08	9							



Project: d3.1.mpp
Date: Sun 24/02/08

Task

Split

Progress

Milestone

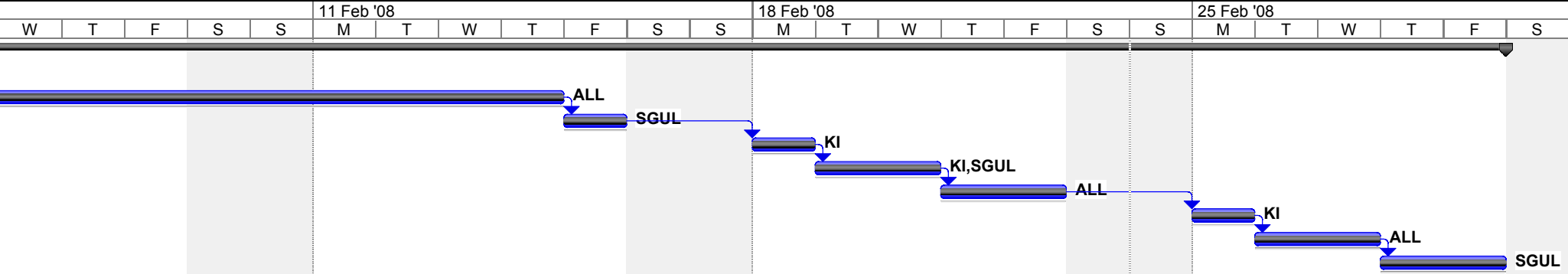
Summary

Project Summary

External Tasks

External Milestone

Deadline



Project: d3.1.mpp
Date: Sun 24/02/08

Task

Split

Progress

Milestone

Summary

Project Summary

External Tasks

External Milestone

Deadline